

## CASE REPORT

# Spontaneous right-sided microcavitations in a healthy adult

Hena Patel MD<sup>1</sup>, Stephen Boateng MD<sup>2</sup>, Gurpreet Singh MD<sup>2</sup> and Steven Feinstein MD FACC FESC<sup>2</sup>

<sup>1</sup>Division of Internal Medicine, and <sup>2</sup>Division of Cardiology, Rush University Medical Center, 1653 West Congress Parkway, Chicago, Illinois 60612, USA

Correspondence should be addressed to H Patel  
**Email**  
henapatel87@gmail.com

## Summary

Spontaneous echo contrast (SEC) is frequently observed in patients with structural and functional cardiovascular abnormalities. Literature describes cases of SEC either from agglutination of red blood cells and plasma proteins or from microcavitations. SEC secondary to the former is an independent predictor of future thromboembolic events and is most commonly observed in the left atrium or left atrial appendage. Thus, many authors reason that left atrial SEC is an indication for initiating anticoagulant therapy. We report a rare case of right atrial SEC that was incidentally found during echocardiographic evaluation of isolated peripheral edema in a healthy adult with a structurally normal heart. At present, there are no studies to offer guidance for management of right atrial SEC. This case emphasizes a necessary area of future research.

## Learning points:

- Cardiovascular implications of SEC.
- Diagnostic evaluation and management of SEC.

## Background

Spontaneous echo contrast (SEC) due to red blood cells (RBC) and plasma proteins is echocardiographically characterized by a fine granular or particulate echo-dense whirling pattern within the cardiac chambers or vessels, also referred to as 'smoke'. It is caused by increased ultrasonic backscatter from blood cell aggregates that form under low shear conditions, and is strongly associated with thrombus formation and systemic thromboembolism (1). Conversely, microcavitations present with echocardiographically distinct findings compared to SEC from blood aggregates. Typically observed with mechanical prosthetic valves, they are characterized by a discontinuous stream of rounded, strongly echogenic, rapidly moving transient echoes and are thought to result from gas bubble formation at a local site of rapid pressure decrease as the prosthetic valve closes (2). Detection of

microcavitations has increased considerably with the advent of second harmonic imaging in echocardiography, but are often misdiagnosed for masses, thrombi or vegetations associated with mechanical valves. Reports of spontaneous microbubbles in the absence of prosthetic devices are very rare. They may be formed by gas absorbed from the intestine, which reaches the heart through portal and systemic vein shunts (2).

Although most often detected in the left atrium and left atrial appendage, SEC has also been described within the left ventricle, right atrium, descending aorta and pulmonary artery. We report the occurrence of spontaneous contrast in the right atrium the absence of valvular lesion, chamber dilatation or ventricular dysfunction. To our knowledge, there are no other reports of right-sided SEC in a healthy adult. While left atrial SEC is identified as indication for offering anticoagulant therapy,

data is limited for management of right atrial SEC. Given its potentially devastating complications, further research in this area is needed.

## Case report

A 75-year-old female presented to her primary care physician for pre-operative cardiac risk stratification with progressive lower extremity edema. Review of systems revealed an unintentional weight loss of ~90 pounds over the past year. Physical examination was only remarkable for bilateral lower extremity pitting edema. Her past medical history was notable for ischemic cerebrovascular accident (CVA) and normocytic anemia.

## Investigation

A transthoracic echocardiogram (TTE) was subsequently ordered and showed SEC in the right atrium and right ventricle (Fig. 1). It was otherwise unremarkable, with normal function and structure of all cardiac chambers and valves.

The extraordinary TTE findings led us to review this case in detail. We found that recent laboratory investigations showed a decreased hemoglobin of 7.6 g/dl, hematocrit of 25.8, mean corpuscular volume (MCV) of 88.7 (within normal range of reference lab values) and platelet count of 303/ $\mu$ g. Serum electrolytes were normal, and recent electrocardiogram showed normal sinus rhythm. We further reviewed testing obtained during hospitalization a year prior for workup of an ischemic CVA. At that time, the patient's hemoglobin was 11.6 g/dl

and hematocrit 36.2. TTE did not show SEC, but was otherwise unchanged. MRI brain with fluid attenuation inversion recovery (FLAIR) demonstrated moderate chronic small-vessel disease, which was likely the mechanism of our patient's previous stroke. Endoscopic evaluation revealed gastric ulcers as the culprit of iron deficiency anemia; no hematological disorders were identified.

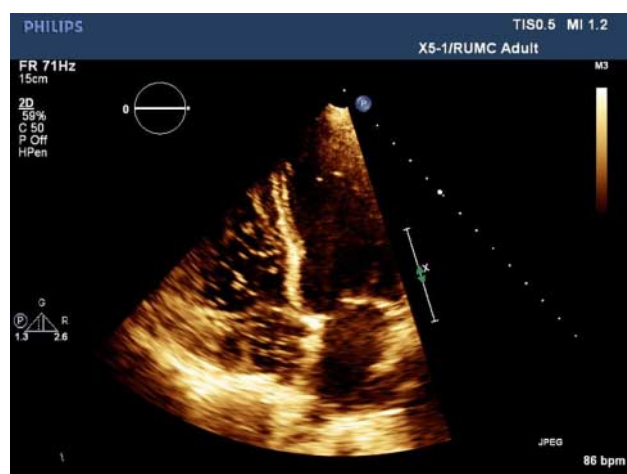
## Treatment and outcomes

Based on these findings and absence of cardiovascular symptoms, the risk of thromboembolism was considered to be very low. The SEC was determined to be of little clinical significance with no cardiovascular implications, and no further testing was pursued.

## Discussion

Spontaneous contrast on echocardiography is frequently found in patients with atrial fibrillation, mitral stenosis or history of thromboembolism, occurring in 30–60% of such patients (3). Though less common, right atrial SEC has been documented in patients with a dilated right atrium associated with atrial arrhythmias or right ventricular systolic dysfunction (4). The pathogenesis of SEC is not clearly established. In addition to atrial fibrillation and structural cardiovascular abnormalities, other entities have been implicated, including aging, low blood flow velocities, low shear rates, high erythrocyte sedimentation rate, increased serum fibrinogen levels and elevated hematocrit levels (1). *In vitro* studies demonstrated that SEC reflects an interaction between RBC and plasma proteins, particularly fibrinogen, but does not require platelets (5). Studies show a stoichiometric relationship between RBC and fibrinogen in SEC formation (5, 6). At lower hematocrit levels, a higher fibrinogen concentration is required for SEC formation, and vice versa. SEC density is determined by flow rate and the relative concentrations of RBC and fibrinogen. Alternately, SEC can be produced from microcavitations, or microbubbles, almost exclusively associated with mechanical valves. Microcavitations are transient embolic echoes produced from stable gas bubble formation at a local site of rapid pressure decrease as the mechanical valve closes, and less commonly when the valve opens (2). They are more discrete and larger than typical SEC and appear to move more rapidly (2).

A structurally normal heart is not thought to be at risk of SEC. Our patient with a normal heart in both structure and function is an unlikely candidate for SEC from either aggregation or microcavitations, especially in the right



**Figure 1**

Spontaneous microbubbles are demonstrated passing from the inferior vena cava into the right atrium and right ventricle.

atrium, which is most commonly observed with right atrial enlargement, elevated right ventricular pressure, atrial fibrillation and tricuspid regurgitation (7). Rare cases of right heart SEC in patients with autoimmune hemolytic anemia have been reported. Close review of our patient's medical history raised suspicion for malignancy based on the presence of iron deficiency anemia, gastric ulcers, non-cardiac edema and significant weight loss, although no formal diagnosis is yet established. Thus, it is possible that our patient's SEC was due to aggregation of blood products from a hypercoagulable state. Interestingly, analysis of her TTE images demonstrated discrete bright, rapidly mobile echoes, distinct from the characteristic smoke-like appearance of SEC secondary to RBC aggregation. We suspect that the detected echoes passing through the right heart represented a cluster of microbubbles in transit. Exceedingly rare in an adult with native valves, this phenomenon may represent an undetected portacaval shunt in our patient. While portasystemic communications are generally surgically introduced, there is a case of spontaneous portacaval shunting occurring in a patient with gastric cancer, which remains a concern in our patient (8).

SEC is a risk factor for thromboembolic events and serves as an indication for anticoagulation (1). Studies have shown that the rate of stroke or other thromboembolic events are higher in patients with SEC compared to their counterparts with structurally abnormal hearts and chronic arrhythmias but no SEC (9). Anticoagulation with warfarin is the current approach in preventing thromboembolism in patients with left atrial SEC. Anticoagulation does not prevent RBC aggregation or SEC production *in vitro*, but it reduces development of thromboembolism. Yasuoka *et al.* (10) studied the relationship between right atrial SEC and silent pulmonary embolism in patients with nonvalvular atrial fibrillation, and determined that right atrial SEC may be a predictor of pulmonary embolism. Studies in animal models and humans have also demonstrated clinically detrimental effects of microbubbles. Circulating in the bloodstream, they can lodge within the lung's capillary bed, obstructing blood flow and causing tissue ischemia. An inflammatory response and complement activation ensue, initiating platelet aggregation and clot formation, and ultimately leading to further obstruction of microcirculation and tissue damage (2). Additionally, formation of stable microbubbles may result in gaseous emboli and secondarily cause transient ischemic attacks or strokes. As such, the risk of future thromboembolism is concerning in our case regardless of underlying etiology. Unfortunately, there is no data available at present for guidance.

In conclusion, we present a unique case of right atrial SEC in a healthy adult with a structurally normal heart. It is possible that normocytic anemia is an independent predictor of SEC in this patient, as well as future thromboembolism. Further research is needed to address alternate causes of spontaneous contrast, and whether anticoagulation should be offered to patients with SEC even with a structurally normal heart.

#### Declaration of interest

The authors declare that there is no conflict of interest that could be perceived as prejudicing the impartiality of the research reported.

#### Funding

This case report did not receive any specific grant from any funding agency in the public, commercial or not-for-profit sector.

#### Patient consent

Written consent was obtained.

#### Author contribution statement

H Patel wrote the manuscript and completed a literature review. G Singh reviewed the manuscript prior to submission and assisted with review of the literature and included images. S Boetang reviewed the manuscript before submission and obtained the included echocardiography images. S Feinstein was responsible for interpretation of the echocardiography used for establishing the diagnosis, and also reviewed the case report before submission.

#### References

- 1 Black IW 2000 Spontaneous echo contrast: where there's smoke there's fire. *Echocardiography* **17** 373–382. (doi:10.1111/j.1540-8175.2000.tb01153.x)
- 2 Barak M & Katz Y 2005 Microbubbles: pathophysiology and clinical implications. *Chest* **128** 2918–2932. (doi:10.1378/chest.128.4.2918)
- 3 Sadanandan S & Sherrid M 2000 Clinical and echocardiographic characteristics of left atrial spontaneous echo contrast in sinus rhythm. *Journal of the American College of Cardiology* **35** 1932–1938. (doi:10.1016/S0735-1097(00)00643-4)
- 4 Bashir M, Asher CR & Garcia MJ 2001 Right atrial spontaneous echo contrast and thrombus in atrial fibrillation: a transesophageal study. *Journal of the American Society of Echocardiography* **14** 122–127. (doi:10.1067/mje.2001.108668)
- 5 Rastegar R, Harmick DJ & Weidemann P 2003 Spontaneous echo contrast video density is flow related and is dependent on the relative concentration of fibrinogen and red blood cells. *Journal of the American College of Cardiology* **41** 603–610. (doi:10.1016/S0735-1097(02)02898-X)
- 6 Kwaan HC, Sakurai S & Wang J 2003 Rheological abnormalities and thromboembolic complications in heart disease: spontaneous contrast and red cell aggregation. *Seminars in Thrombosis and Hemostasis* **29** 529–534. (doi:10.1055/s-2003-44559)
- 7 DeGeorgia MA, Chimowitz MI, Hepner A & Armstrong WF 1994 Right atrial spontaneous contrast: echocardiographic and clinical features.

- International Journal of Cardiovascular Imaging* **10** 227–232. (doi:10.1007/BF01137904)
- 8 Takeda J, Hashimoto K & Tanaka T 1991 Spontaneous portacaval shunts in patients with gastric cancer and hepatic cirrhosis. *Kurume Medical Journal* **38** 33–37. (doi:10.2739/kurumemedj.38.33)
  - 9 Handke M, Harloff A, Hefzel A, Olschewski M, Bode C & Geibel A 2005 Predictors of left atrial spontaneous echocardiographic contrast or thrombus formation in stroke patients with sinus rhythm and reduced left ventricular function. *American Journal of Cardiology* **96** 1342–1344. (doi:10.1016/j.amjcard.2005.06.085)
  - 10 Yasuoka Y, Naito J & Hirooka K 2009 Right atrial spontaneous echocontrast indicates a high incidence of perfusion defects in pulmonary scintigraphy in patients with atrial fibrillation. *Heart and Vessels* **24** 32–36. (doi:10.1007/s00380-008-1084-3)

---

Received in final form 5 June 2015

Accepted 11 June 2015