

## GUIDELINES AND RECOMMENDATIONS

# Echocardiographic assessment of pulmonary hypertension: a guideline protocol from the British Society of Echocardiography

**Daniel X Augustine MD<sup>1,\*</sup>, Lindsay D Coates-Bradshaw<sup>2</sup>, James Willis PhD<sup>1</sup>, Allan Harkness MSc<sup>3</sup>, Liam Ring<sup>4</sup>, Julia Grapsa PhD<sup>5</sup>, Gerry Coghlan MD<sup>6</sup>, Nikki Kaye<sup>7</sup>, David Oxborough PhD<sup>8</sup>, Shaun Robinson MSc<sup>9</sup>, Julie Sandoval<sup>10</sup>, Bushra S Rana FRCP<sup>11</sup>, Anjana Siva<sup>12</sup>, Petros Nihoyannopoulos MD<sup>13</sup>, Luke S Howard DPhil<sup>14</sup>, Kevin Fox FRCP<sup>15</sup>, Sanjeev Bhattacharyya MD<sup>16</sup>, Vishal Sharma MD<sup>17,†</sup>, Richard P Steeds MD<sup>18</sup> and Thomas Mathew<sup>2,†</sup> on behalf of the British Society of Echocardiography Education Committee**

<sup>1</sup>Royal United Hospital Bath NHS Foundation Trust, Bath, UK

<sup>2</sup>Nottingham University Hospitals NHS Trust, Nottingham, UK

<sup>3</sup>Colchester Hospital NHS Trust, Colchester, UK

<sup>4</sup>West Suffolk Hospital NHS Trust, Bury St Edmunds, UK

<sup>5</sup>Hammersmith Hospital, Imperial College London, London, UK

<sup>6</sup>Royal Free London NHS Foundation Trust – Cardiology, London, UK

<sup>7</sup>West Suffolk NHS Foundation Trust, Bury Saint Edmunds, UK

<sup>8</sup>Liverpool John Moores University, Research Institute for Sports and Exercise Physiology, Liverpool, UK

<sup>9</sup>Papworth Hospital NHS Foundation Trust, Cambridge, UK

<sup>10</sup>Leeds Teaching Hospitals NHS Trust, Leeds, UK

<sup>11</sup>Papworth Hospital, Cambridge, UK

<sup>12</sup>Queen Alexandra Hospital, Portsmouth, UK

<sup>13</sup>Imperial College London, NHLI, National Heart & Lung Institute, London, UK

<sup>14</sup>Imperial College London, National Pulmonary Hypertension Service, London, UK

<sup>15</sup>Hammersmith Hospital, London, UK

<sup>16</sup>St Bartholomew's Hospital, Barts' Heart Centre, London, UK

<sup>17</sup>Royal Liverpool and Broadgreen University Hospitals NHS Trust, Liverpool, UK

<sup>18</sup>University Hospital Birmingham and University of Birmingham, Birmingham, UK

Correspondence should be addressed to D Augustine: [daniel.augustine@nhs.net](mailto:daniel.augustine@nhs.net)

\*(D Augustine is the Lead Author)

†(Guideline Chairs: T Mathew and V Sharma)

The publication of this article was sponsored by Actelion Pharmaceuticals Ltd. The article was produced by the British Society of Echocardiography independently of Actelion Pharmaceuticals Ltd and they were not able to influence its content. Peer review was carried out independently by the journal's editorial board, based on scientific merit alone.

## Abstract

Pulmonary hypertension is defined as a mean arterial pressure of  $\geq 25$  mmHg as confirmed on right heart catheterisation. Traditionally, the pulmonary arterial systolic pressure has been estimated on echo by utilising the simplified Bernoulli equation from the peak tricuspid regurgitant velocity and adding this to an estimate of right atrial pressure. Previous studies have demonstrated a correlation between this estimate of pulmonary arterial systolic pressure and that obtained from invasive measurement across a cohort of patients. However, for an individual patient significant overestimation and underestimation can occur and the levels of agreement between the two is poor. Recent guidance has suggested that echocardiographic assessment of pulmonary hypertension should be limited to determining the probability of pulmonary hypertension being present rather than estimating the

## Key Words

- pulmonary hypertension
- echocardiography
- guideline

pulmonary artery pressure. In those patients in whom the presence of pulmonary hypertension requires confirmation, this should be done with right heart catheterisation when indicated. This guideline protocol from the British Society of Echocardiography aims to outline a practical approach to assessing the probability of pulmonary hypertension using echocardiography and should be used in conjunction with the previously published minimum dataset for a standard transthoracic echocardiogram.

## Introduction

The British Society of Echocardiography (BSE) Education Committee has previously published a minimum dataset for a standard adult transthoracic echocardiogram (1). This document specifically states that the minimum dataset is usually only sufficient when the echocardiographic study is entirely normal. However, the BSE Education Committee has published a number of supplementary guidelines to cover specific pathologies to be utilised in conjunction with this minimum dataset.

The intended benefits of such supplementary recommendations are to:

- Support cardiologists and echocardiographers to develop local protocols and quality control programmes for an adult transthoracic study.
- Promote quality by defining a set of descriptive terms and measurements, in conjunction with a systematic approach to performing and reporting a study in specific disease states.
- Facilitate the accurate comparison of serial echocardiograms performed in patients at the same or different sites.

In this guideline, the important measurements that should be performed when assessing a patient's probability of having pulmonary hypertension (PH) are discussed. Some of these views are part of the minimum dataset but the majority are additional. The aim of this document is to provide practical recommendations for the image and analysis dataset required in patients being assessed for possible PH, or where the diagnosis is known and is consistent with the 2015 European Society of Cardiology/European Respiratory Society recommendations on the diagnosis and treatment of PH (2). Estimation of PH in patients with left heart disease such as valvular heart disease remains within current guidelines (3, 4, 5). Estimation of pulmonary artery pressure (PAP) within these patients is reasonable, at rest and during exercise (3, 6) or during follow-up of an individual patient. However, confirmation with

right heart catheterisation (RHC) should be considered, particularly if the presence of PH is a major component of any decision to refer for intervention.

This guideline replaces the previous protocol on PH published by the BSE and will be reviewed and updated in the future as a result of future publications or changes in best practice.

## Background

PH is presently defined as an increase in mean pulmonary arterial pressure to  $\geq 25$  mmHg at rest as assessed by right heart catheterisation (2). The clinical significance of a mean pulmonary arterial pressure between 21 mmHg and 24 mmHg is unclear. It can complicate many cardiovascular, respiratory and connective tissue diseases. Untreated, morbidity and mortality levels are high (7, 8) and therefore accurate and prompt diagnosis is crucial. The diagnosis of PH requires a clinical suspicion based on symptoms, physical examination and review of a comprehensive set of investigations. Echocardiography is a key imaging modality in the assessment of patients with suspected or known PH.

The classification of PH categorises different clinical conditions into five groups (Table 1). This is an important categorisation for two reasons: first, the most common form of PH encountered in any echocardiography department will be secondary to left heart disease (9) and hence a full study with consideration of indirect measures of elevation in left ventricular end-diastolic pressure must be performed in all cases consistent with the minimum dataset (1); secondly, the interpretation of supportive measurements for classification of patients with intermediate probability of PH, such as pulmonary artery acceleration/mid systolic notching, must be taken in the context of the possible underlying cause as these may be more likely in cases with pre-capillary PH.

Each of these groups can further be categorised as to whether there is normal pulmonary arterial wedge

**Table 1** Classification of PH.

WHO group	Aetiology of pulmonary hypertension	Mean pulmonary arterial wedge pressure	Example causes
1	Pulmonary arterial hypertension	Normal	Idiopathic, hereditary, drug or toxin induced, shunts related to congenital heart disease, connective tissue disease, portal hypertension, chronic haemolytic anaemia
2	Pulmonary hypertension secondary to left heart disease	Increased	Valvular heart disease, systolic dysfunction, diastolic dysfunction, pericardial disease, congenital/acquired left heart inflow/outflow tract obstruction, congenital cardiomyopathies
3	Pulmonary hypertension secondary to lung disease	Normal	Chronic obstructive pulmonary disease, severe asthma, interstitial lung disease, sleep apnoea, long term exposure to high altitude, congenital lung abnormalities
4	Chronic thromboembolic pulmonary hypertension (CTEPH)	Normal	Chronic pulmonary embolism
5	Pulmonary hypertension with unclear and/or multifactorial mechanisms	Normal or increased	Systemic diseases, sarcoidosis, vasculitis, haematological malignancies, chronic renal failure, metabolic disorders, lung tumours

Adapted from World Health Organisation Classification of PH (10).

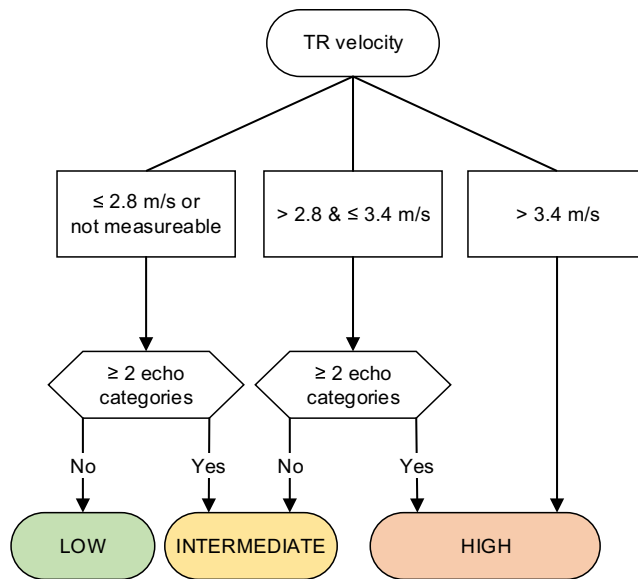
pressure (an estimate of left atrial pressure) or elevated pulmonary arterial wedge pressure, which may be helpful in identifying the aetiology of PH. The World Health Classification of PH is outlined in Table 1.

The traditional echocardiographic approach to estimating pulmonary artery systolic pressure (PASP) uses a derivation of right ventricular pressure from the tricuspid regurgitation (TR) velocity added to a qualitative assessment of right atrial pressure (RAP). Previous studies have demonstrated good correlation across patient populations but only moderate precision of absolute PASP values calculated from TR velocity (TRV)max (11, 12, 13, 14). This is important as in an individual patient, significant under and over estimation can occur leading to misdiagnosis and inappropriate treatment (15).

There are number of reasons why the level of agreement between the estimated pressures derived by echocardiography and those measured invasively is poor. First, errors may occur in accurate measurement of the peak TRV signal. This can result in both over estimation and underestimation if the quality of the Doppler signals is poor or inaccurate as a result of suboptimal Doppler alignment due to eccentric jets. When estimating right ventricular systolic pressure (RVSP) from the TRV using the Bernoulli equation, the TRV is squared and multiplied by 4, so even small errors in the absolute measurement of TRV can result in significant changes to the estimate of RVSP. Secondly, in order to obtain an estimate of PASP, the RVSP

needs to be added to an estimate of the RAP derived from measurement of the inferior vena cava (IVC) dimensions and response to inspiration. However, in many patients, IVC dimensions cannot be obtained and even in those where measurement is possible, the accuracy between echo estimation of RAP and invasive measurement is as low as 34% (16). Thirdly, it is well recognised that in patients with severe free-flowing TR that the correlation between TRV and RVSP is poor and should not be performed (17). In addition, absence of TR is insufficient to exclude the presence of PH. For example, one study has shown that in patients with scleroderma being screened for PH, if a TRV cut-off of 2.7 m/s was used, this would have excluded some patients who had a mean pulmonary arterial pressure >40 mmHg (18). Furthermore, the expected normal upper limit of PASP depends on BMI (19).

In view of these factors, when screening patients with suspected PH, information obtained from echocardiography can only grade the probability of PH being present rather than provide a definitive diagnosis. Therefore, when assessing the probability of PH, the measurement of TRV should be used in conjunction with other echocardiographic markers of PH. Thus, the information in this protocol is intended to be used as a guide and the data have been selected by consensus using as much evidence base as possible. Future studies assessing the accuracy of this probability-based approach in the diagnosis of PH will be beneficial and add to the evidence base. The invasive measurement of



**Figure 1**

Flow chart to assess the probability of pulmonary hypertension using parameters identified from within  $\geq 2$  categories (the ventricles, pulmonary artery or the inferior vena cava and right atrium) in conjunction with tricuspid regurgitation velocity. Adapted from ESC/ERS Guidelines for the diagnosis and treatment of pulmonary hypertension 2015 (2).

pulmonary artery pressure during right heart cardiac catheterisation is required to confirm or refute a diagnosis of PH.

The first step in assessing the echocardiographic probability of PH being present is to measure the peak TRV. If this is a good-quality signal and is greater than 3.4 m/s, there is a high probability of PH being present. If the peak TRV is below 3.4 m/s, the probability of PH is assessed in combination with other echocardiographic markers.

This approach based on estimation of likelihood is recommended for all clinical groups of PH. Additional considerations in specific subsets of patients are included in the 'Appendices' section. The assessment of probability of PH by echocardiography is just one part in the overall clinical judgement as to the presence of PH in a certain individual. Echocardiographic findings should be interpreted alongside other clinical findings to establish the likelihood of PH prior to confirmatory diagnosis as needed by RHC.

## Echocardiographic assessment of patents with PH

The flow chart depicted in Fig. 1 is used to assess the probability of PH. The echocardiographic parameters used for grading the probability of PH are set out in Table 2 and described further in Table 3. If the TRV is  $>3.4$  m/s then the echocardiographic probability of PH is high. If the TRV is  $\leq 3.4$  m/s, then other echocardiographic parameters suggesting PH must be used to assign the probability of PH. These parameters are split into three categories (A: the ventricles; B: the pulmonary artery; C: the IVC and right atrium). Parameters from at least two different categories are needed to determine the probability of PH.

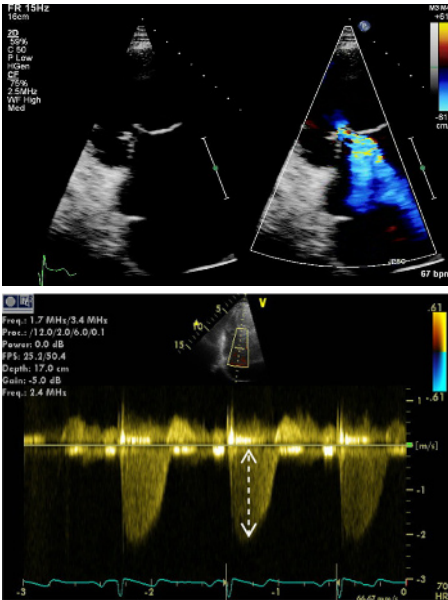
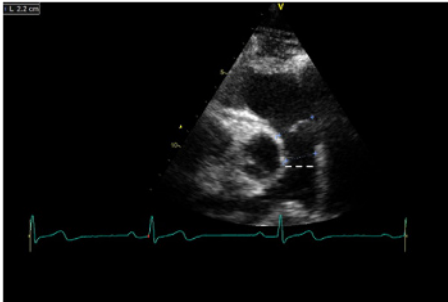
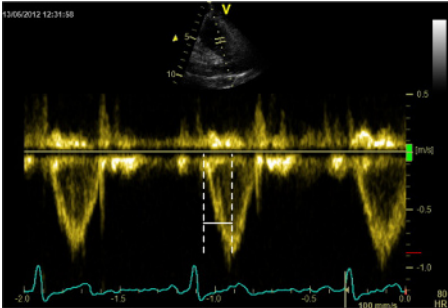
Echocardiography also provides information about aetiology and prognosis in patients with PH. Patients with established PH or high probability for PH should have full assessment to exclude left-sided heart disease or intracardiac shunts as the cause of PH. Right ventricular dilatation and dysfunction are considered poor prognostic markers in patients with PH. Additional measurements that can be used to assess patients with PH are shown in Table 4.

**Table 2** Echocardiographic signs used to help grade the probability of PH.

A: The ventricles <sup>a</sup>	B: Pulmonary artery <sup>a</sup>	C: Inferior vena cava and right atrium <sup>a</sup>
Right ventricle/left ventricle basal diameter ratio $>1.0$	Right ventricular outflow Doppler acceleration time $<105$ ms and/or mid systolic notching	Inferior vena cava diameter $>21$ mm with decreased inspiratory collapse ( $<50\%$ with a sniff or $<20\%$ with quiet respiration)
Flattening of the interventricular septum (left ventricular eccentricity index $>1.1$ in systole or both systole and diastole)	Early diastolic pulmonary regurgitation (PR) velocity $>2.2$ m/s	Right atrial area (end systole) $>18$ cm <sup>2</sup>
	PA diameter $>25$ mm	

<sup>a</sup>Echocardiographic parameters from at least two different categories (A/B/C) from the list should be present to alter the level of echocardiographic probability of pulmonary hypertension.

**Table 3** Minimum requirements needed to assess the probability of pulmonary hypertension.

Measurements	View (modality)	Explanatory note	Image
Peak TR velocity	A4C PSAX/RV inflow (CW)	<p>Peak TRV is measured by CW Doppler across the tricuspid valve. Multiple views may need to be taken to obtain the optimal window. These include the RV inflow, parasternal short axis (PSAX), apical 4-chamber (A4C) view, subcostal view or a modified view between the PSAX and A4C (20)</p> <p>Ensure the CW Doppler to flow angle is correctly aligned. Eccentric jets can lead to incomplete Doppler envelopes and underestimation of TR velocity. A high sweep speed (100 mm/s) (21) can help to differentiate between true velocities and artefact</p> <p>Velocity can be under estimated in severe/free TR and should be stated in the report (see 'Appendices' section)</p> <p>Measure from a complete TR envelope. Choose the highest velocity (average of five beats in atrial fibrillation)</p> <p>A TRV &lt;2.8m/s is considered normal (2, 22)</p>	
Pulmonary artery (PA) diameter	PSAX (2D)	<p>PA dimension is measured in end diastole halfway between the PV and bifurcation of main PA (21)</p> <p>The PA dilates in response to volume and pressure overload</p> <p>A diameter of &gt;25mm is considered abnormal (2)</p>	
RV outflow tract (RVOT) acceleration time (AT)	PSAX (PW)	<p>A pulsed wave (PW) Doppler measurement taken after positioning the sample volume just below the pulmonic cusp on the RV side in the RV outflow tract (23)</p> <p>Measure at end expiration from the onset of flow to peak flow velocity. As pulmonary artery pressure (PAP) increases, the acceleration time of the RV ejection into the PA shortens</p> <p>Use the average of five beats in atrial fibrillation. Heart rates outside of the normal range (&lt;70 or &gt;100 bpm) may reduce accuracy and a correction for heart rate (HR) may be used (RVOT AT × 75/HR) (24, 25, 26)</p> <p>When pulmonary pressures measured invasively are &gt;25mmHg, changes in heart rate have no significant effect on acceleration time (25)</p> <p>Acceleration time of &lt;105 ms is considered a marker of raised PAP (27)</p>	

(Continued)

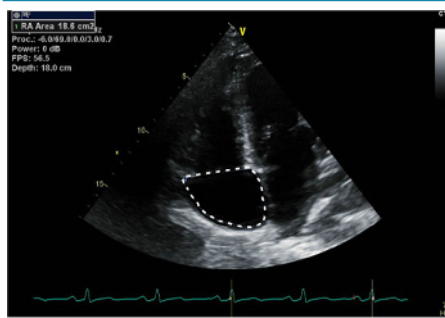
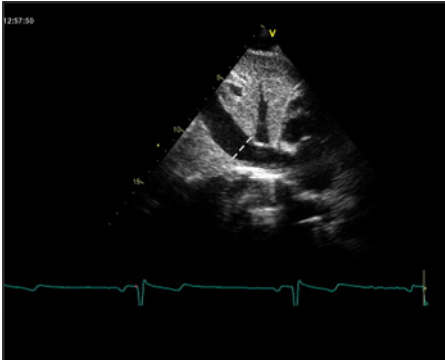


**Table 3** Continued.

Measurements	View (modality)	Explanatory note	Image
Early diastolic PR velocity	PSAX or parasternal RV outflow view (CW)	A CW Doppler measurement through the pulmonary valve in line with the PR jet. Multiple views may be needed to obtain the best PR signal. The peak (early/beginning of diastole) PR velocity (PRV <sub>BD</sub> ) value is measured. This may have additional value when TRV cannot be used or relied upon An early PR velocity >2.2 m/s is considered a marker of raised mean PAP (2)	
Pulmonary systolic notch	PSAX (PW)	A PW Doppler measurement taken after positioning the sample volume just below the pulmonic cusp on the RV side in the RV outflow tract (15) Increased pulmonary vascular resistance and pulmonary arterial stiffness can cause a reflection of waves which return towards the RV during systole. This impedes RV ejection and causes 'notching' of the Doppler profile The presence of a pulmonary systolic notch is considered a marker of raised PAP The presence of a pulmonary mid systolic notch is more likely to represent increased pulmonary vascular resistance and poor vascular compliance in keeping with pre-capillary PH, rather than PH due to left heart disease (28)	
Eccentricity index (EI)	PSAX (2D)	Measure from PSAX view at mid LV level between papillary muscle and tips of mitral valve leaflets. End systole is taken as the frame with the smallest LV cavity; end diastole is measured on the peak of the R-wave (29) The ratio of the minor axis dimensions as shown in the image (D2/D1) measured at end systole and end diastole. D1=left ventricular diameter perpendicular to the septum; D2=left ventricular diameter parallel to the septum RV pressure and volume overload can lead to an abnormal shape and function of the interventricular septum, resulting in flattening RV volume overload causes eccentricity in diastole only. RV pressure overload also causes eccentricity in systole. Off-axis PSAX images may cause artefactual eccentricity Left ventricular eccentricity index >1.1 is considered abnormal (2)	
RV/LV basal diameter ratio	A4C (2D)	This is measured from the standard A4C view without foreshortening. Measurement is taken at end diastole Ratio of >1 measured at end diastole suggests RV dilatation (2)	

(Continued)

**Table 3** Continued.

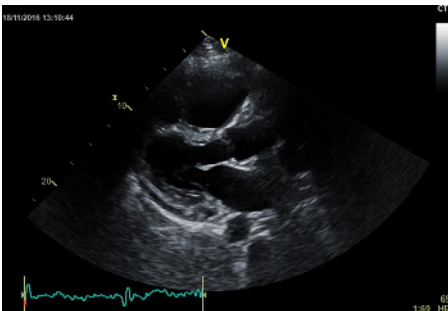
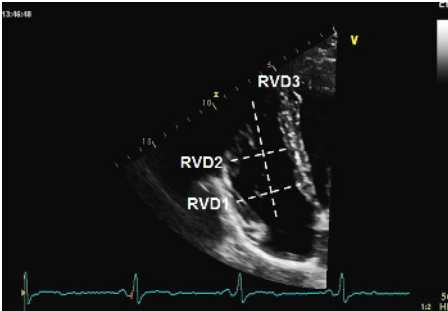
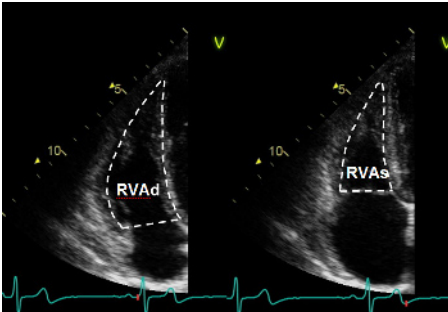
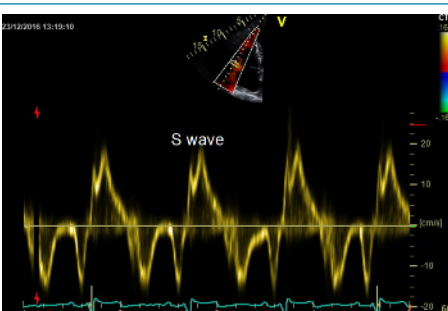
Measurements	View (modality)	Explanatory note	Image
Right atrial area	A4C (2D)	Measure at end ventricular systole on the frame just prior to tricuspid valve opening Trace the RA from the plane of the TV annulus along the IAS, superior and lateral walls of RA RAA >18 cm <sup>2</sup> is considered abnormal (21, 30)	
Inferior vena cava diameter (IVC)	Subcostal (2D M-mode)	Diameter is measured perpendicular to the IVC long axis, 1–2 cm from the RA junction at end expiration Assess size and percentage reduction in diameter with sniffing or quiet inspiration IVC diameter >21 mm with decreased inspiratory collapse (<50% with a sniff or <20% with quiet respiration) is considered abnormal (2)	

## Additional measurements

Although not required when determining the likelihood of PH being present, a number of other echo markers can be useful in determining the severity of PH and may provide additional prognostic information (Table 4). These are particularly useful in those patients with a

confirmed diagnosis of PH. These markers include right ventricular dimensions (RVD1 RVD2, RVD3), fractional area change and tricuspid annular plane systolic excursion (TAPSE). In addition, the peak systolic RV pulsed tissue Doppler velocity taken at the lateral tricuspid annulus and right ventricular index of myocardial performance (RIMP) can provide further information.

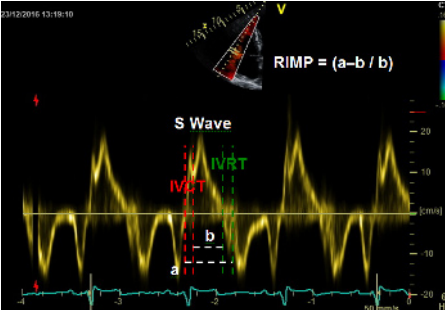
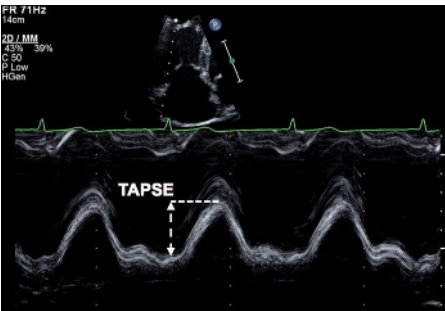
**Table 4** Useful additional features and prognostic findings in patients with established PH.

Measurements	View (modality)	Explanatory note	Image
Pericardial effusion	All views (2D)	The presence of a pericardial effusion due to PH is a sign of advanced disease with poor prognosis (31, 32)	
RV dimensions (RVD1, RVD2, RVD3)	A4C (2D)	<p>Due to increasing preload and afterload, progressive right ventricular dilatation is seen with worsening pulmonary hypertension</p> <p>All measurements are taken at end diastole in the RV-focused view (33). RV size may be underestimated due to the crescentic RV shape</p> <p>RVD1: Basal RV diameter. Measured at the maximal transverse diameter in the basal one third of the RV. RVD1 &gt;41 mm is abnormal (33)</p> <p>RVD2: Mid RV diameter measured at the level of the LV papillary muscles</p> <p>RVD2 &gt;35 mm is abnormal (33)</p> <p>RVD3: RV length (end diastole from the plane of the tricuspid annulus to the RV apex)</p> <p>RVD3 &gt;83 mm is abnormal (33)</p>	
Fractional area change (FAC)	A4C (2D)	<p>Manual tracing of the RV endocardial border from the lateral tricuspid annulus along the free wall to the apex and back along the interventricular septum to medial tricuspid valve annulus at end diastole and end systole. A disadvantage of this measure is that it neglects the contribution of the RV outflow tract to overall systolic function</p> <p><math>FAC = (RVAd - RVAs) / RVAd</math></p> <p>RV FAC &lt;35% indicates RV systolic dysfunction (33)</p>	
RV pulsed tissue Doppler S wave (S) velocity	A4C (PW TDI)	<p>PW tissue Doppler S wave measurement taken at the lateral tricuspid annulus in systole. It is important to ensure the basal RV free wall segment and the lateral tricuspid annulus are aligned with the Doppler cursor to avoid velocity underestimation</p> <p>A disadvantage of this measure is that it assumes that the function of a single segment represents the function of the entire ventricle, which is not likely in conditions that include regionality such as RV infarction (21)</p> <p>S' wave velocity &lt;9.5 cm/s indicates RV systolic dysfunction (33)</p>	

(Continued)



**Table 4** Continued.

Measurements	View (modality)	Explanatory note	Image
Myocardial performance index (RIMP)	A4C (PW or PW TDI)	<p>RIMP is an index of global RV performance. The isovolumic contraction time (IVCT), isovolumic relaxation time (IVRT) and ejection time intervals can be measured using tissue Doppler or pulsed wave Doppler. Pulsed wave Doppler or tissue Doppler methods require a sample positioned at the lateral tricuspid valve annulus. However, RIMP derived from pulsed wave Doppler also requires an additional sample from the RVOT and both pulse wave samples need to have near-identical R-R intervals (i.e. heart rate). Tissue Doppler is preferred as it is derived from a single sample.</p> <p>RIMP &gt;0.43 by pulsed wave Doppler or &gt;0.54 by tissue Doppler indicates RV dysfunction (33)</p> <p>Tissue Doppler values &gt;0.64 are associated with worse prognosis (32)</p>	
Tricuspid Annular Plane Systolic Excursion (TAPSE)	A4C (M-mode)	<p>This is an angle dependent measurement and therefore it is important to align the M-mode cursor along the direction of the lateral tricuspid annulus. Select a fast sweep speed.</p> <p>The excursion of the lateral tricuspid annulus is measured by M-mode between end diastole and peak systole.</p> <p>A measure of longitudinal RV systolic function. TAPSE &lt;1.7 cm is highly suggestive of RV systolic dysfunction (33)</p>	

## Other echocardiographic measurements

In addition to the echocardiographic measures discussed in this document, there are other echocardiographic markers that may be of use in assessing patients with PH. These measures include stroke volume, cardiac output and pulmonary vascular resistance, although the value of serial measures of these by echocardiography has not been validated. These measures may be of value where further haemodynamic information is required:

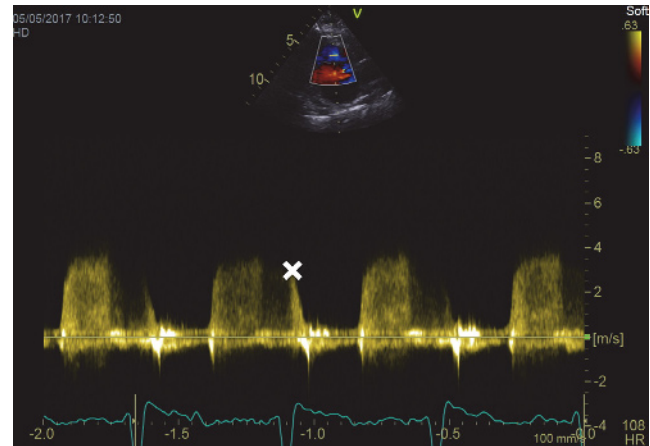
- Pulmonary arterial end-diastolic pressure (PDP). Measure pulmonary regurgitant jet velocity taken at end diastole ( $PRV_{ED}$ ) (Fig. 2).

$$PDP = 4(PRV_{ED})^2 + RAP$$

- Mean pulmonary artery pressure (31). Measure pulmonary regurgitant jet velocity taken at the beginning of diastole ( $PRV_{BD}$ ).

$$\text{Mean PAP} = 4(PRV_{BD})^2 + RAP$$

- Surrogates of heart function (e.g. stroke volume index and cardiac index) have been shown to be associated with prognosis (32, 34). It is possible to estimate these values using echocardiography (Table 5) although the preferred option would be by thermodilution at RHC (2).



**Figure 2**

Measurement of pulmonary regurgitant jet at end diastole (marked X).

- Pulmonary vascular resistance (PVR) can be measured using TRV (m/s) and  $VTI_{RVOT}$  (cm):

$PVR \text{ (Wood units)} = 10 \times (TRV / VTI_{RVOT}) + 0.16$ . Here, a  $TRV / VTI_{RVOT} < 0.2$  corresponds approximately to a PVR of  $< 2$  Wood units (35).

**Table 5** Calculations to assess markers of ventricular function.

Measure	Echocardiographic assessment
Cross sectional area (CSA) left ventricular outflow tract (LVOT)	$(LVOT \text{ diameter})^2 \times 0.785$
Stroke volume (SV)	$\text{Velocity time integral (VTI)}_{(LVOT)} \times \text{Cross sectional area (CSA)}_{(LVOT)}$
Cardiac output (CO)	$\text{Stroke volume} \times \text{heart rate (HR)}$
Stroke volume index (SVi)	$\text{Stroke volume/body surface area (BSA)}$
Cardiac index (CI)	$CO/BSA$

## Appendices

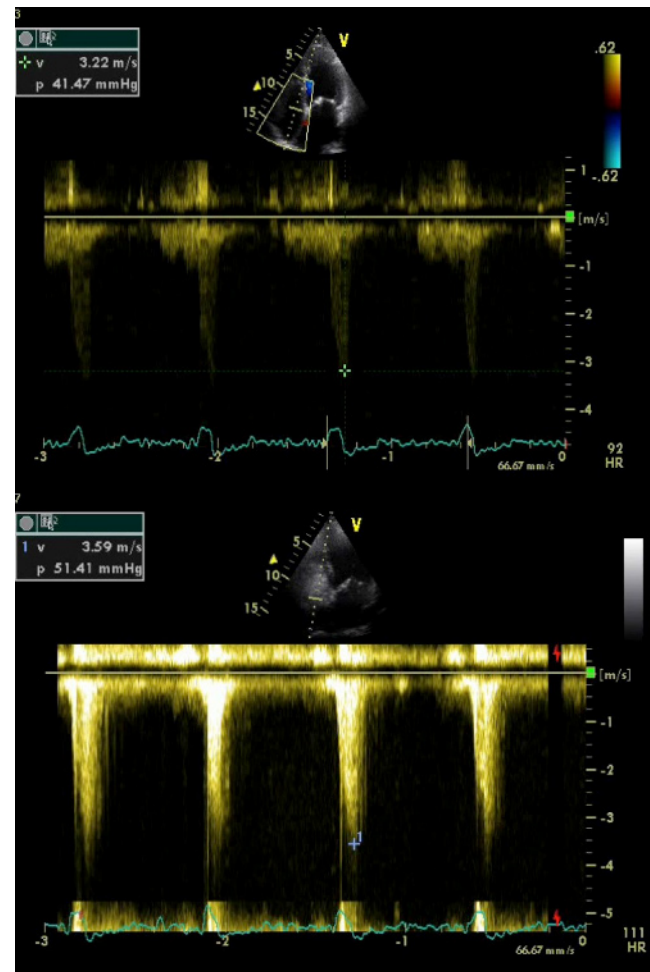
### TR assessment

Peak TR velocity is the key parameter in determining the probability of PH, but the TR signal can be absent in a proportion of patients. The prevalence of TR in patients with a PASP  $\geq 35$  mmHg is only 80% but increases to greater than 95% in those with PASP  $>50$  mmHg (36). If the TR signal is absent, probability estimation should be based on clinical context taking into consideration other concordant clinical and echocardiographic signs of RV pressure overload (Fig. 1). In patients with a trivial TR jet or sub optimal continuous wave Doppler spectrum, injection of intravenous agitated saline can be considered to improve the Doppler signal allowing measurement of peak TR velocity (37) (Fig. 3). As a default, if clinical suspicion remains, invasive measurement of pulmonary pressures should be recommended.

In patients with severe TR, TR velocity can be significantly underestimated and cannot be used alone to exclude PH. The severity of the volume of TR is distinct from velocity and the probability of PH in this context should be determined in conjunction with other echocardiographic parameters (Fig. 1).

### Assessment of PH in patients with left heart disease

This guideline endorses the use of a probability-based approach for the assessment of PH in all clinical subgroups including those secondary to left-sided heart disease. A full assessment including history, ECG and echocardiography will help to identify PH due to left heart disease (38). This is important as left heart disease will be the major aetiology of PH encountered in echocardiography departments (9). If there is an intermediate or high probability of PH then further echocardiographic evaluation should be made to exclude a cardiac cause for PH. In particular, this should prompt a careful assessment of LV systolic and diastolic function, measurement of left atrial volume and exclusion of left-sided valve disease (Table 6). Colour flow Doppler should



**Figure 3**  
TR jet obtained at baseline (top) is improved following injection of intravenous agitated saline (bottom).

be used to exclude atrial and ventricular septal defects. Following a thorough clinical review, a bubble study and transoesophageal echocardiogram may be considered to fully exclude cardiac causes of PH, especially in those patients with confirmed PH.

It is recognised that some guidelines use an absolute PASP value to guide management of patients with PH secondary to left heart disease. In patients with severe

**Table 6** Features which may suggest left heart disease causing PH.

PH due to left heart disease group	Echocardiographic features suggesting left heart disease may be cause of PH
LV systolic dysfunction	Dilated LV; reduced LV ejection fraction
LV diastolic dysfunction	E/e' $>10$ (39); left atrial dilatation (40); left ventricular hypertrophy (38)
Valvular heart disease	$>$ Mild valvular disease
Congenital heart disease	Presence of intra and extra cardiac defects

mitral valve disease, a PASP >50 mm Hg is considered a class IIa indication for surgery (3, 4). Evidence for this is largely based on invasive pulmonary artery pressure measurements, but there are limited echocardiographic studies suggesting a prognostic role for PASP derived from TR velocity and RA pressure (41, 42). In this subset of patients, in addition to determining probability of PH using TR velocity, resting PASP can be estimated by echocardiography using standard methods (4). Confirmation by invasive measurement is required before considering valve surgery if elevated PASP is the main or only reason triggering intervention.

## Key messages

In patients with suspected PH, the following echo parameters should be used to assess the probability of PH:

1. Peak TR velocity
2. Ventricle
  - a. Eccentricity index
  - b. Basal LV/RV diameter ratio
3. PA
  - a. RVOT acceleration time and/or mid systolic notching
  - b. Early diastolic PR velocity
  - c. PA diameter
4. RA and IVC
  - a. RA area
  - b. IVC size and respiratory variability

## Conclusion

Echocardiography should be used to assess the probability of PH being present. Confirmation with right heart catheterisation is warranted if a definitive diagnosis of PH is needed, particularly if pre-capillary PH-specific therapies may be indicated.

## Abbreviations

A4C	Apical four chamber
AT	Acceleration time
BSA	Body surface area
BSE	British Society of Echocardiography
CI	Cardiac index
CO	Cardiac output
CW	Continuous wave
DT	Deceleration time
EI	Eccentricity index
FAC	Fractional area change
HR	Heart rate
IVC	Inferior vena cava
IVCT	Isovolumetric contraction time
IVRT	Isovolumetric relaxation time
LA	Left atrium
LV	Left ventricle
PA	Pulmonary artery
PAP	Pulmonary artery pressure
PASP	Pulmonary artery systolic pressure
PDP	Pulmonary arterial end diastolic pressure
PH	Pulmonary hypertension
PHT	Pressure half-time
PR	Pulmonary regurgitation
PRV <sub>BD</sub>	Pulmonary regurgitant velocity at the beginning of diastole
PRV <sub>ED</sub>	Pulmonary regurgitant velocity at the end of diastole
PS	Pulmonary stenosis
PSAX	Parasternal short axis
PV	Pulmonary valve
PVR	Pulmonary vascular resistance
PW	Pulsed wave
RA	Right atrium
RAA	Right atrial area
RAP	Right atrial pressure
RHC	Right heart catheterisation
RIMP	Right ventricular index of myocardial performance
RV	Right ventricle
RVAd/s	Right ventricular area in diastole/systole
RVD	Right ventricular diameter
RVOT	Right ventricular outflow tract
RVSP	Right ventricular systolic pressure
SV	Stroke volume
SVi	Stroke volume index
TAPSE	Tricuspid annular plane systolic excursion
TR	Tricuspid regurgitation
TRV	Tricuspid regurgitation velocity
TV	Tricuspid valve
Vmax	Maximum velocity
VTI	Velocity time integral

# Declaration of interest

The authors declare that there is no conflict of interest that could be perceived as prejudicing the impartiality of this guideline.

# Funding

The publication of this article was sponsored by Actelion Pharmaceuticals Ltd. The article was produced by the British Society of Echocardiography independently of Actelion Pharmaceuticals Ltd, and they were not able to influence its content. Peer review was carried out independently by the journal's editorial board, based on scientific merit alone.

# References

- Wharton G, Steeds R, Allen J, Phillips H, Jones R, Kanagala P, Lloyd G, Masani N, Mathew T, Oxborough D, *et al.* A minimum dataset for a standard adult transthoracic echocardiogram: a guideline protocol from the British Society of Echocardiography. *Echo Research and Practice* 2015 **2** G9–G24. (<https://doi.org/10.1530/ERP-14-0079>)
- Galie N, Humbert M, Vachieri JL, Gibbs S, Lang I, Torbicki A, Simonneau G, Peacock A, Vonk Noordegraaf A, Beghetti M, *et al.* 2015 ESC/ERS Guidelines for the diagnosis and treatment of pulmonary hypertension: the joint task force for the diagnosis and treatment of pulmonary hypertension of the European Society of Cardiology (ESC) and the European Respiratory Society (ERS): endorsed by: Association for European Paediatric and Congenital Cardiology (AEPC), International Society for Heart and Lung Transplantation (ISHLT). *European Heart Journal* 2016 **37** 67–119. (<https://doi.org/10.1093/eurheartj/ehv317>)
- Baumgartner H, Falk V, Bax JJ, De Bonis M, Hamm C, Holm PJ, Lung B, Lancellotti P, Lansac E, Munoz DR, *et al.* 2017 ESC/EACTS Guidelines for the management of valvular heart disease. *European Heart Journal* 2017 **38** 2739–2791. (<https://doi.org/10.1093/eurheartj/ehx391>)
- Nishimura RA, Otto CM, Bonow RO, Carabello BA, Erwin JP, Fleisher LA, Jneid H, Mack MJ, McLeod CJ, O'Gara PT, *et al.* 2017 AHA/ACC focused update of the 2014 AHA/ACC Guideline for the management of patients with valvular heart disease: a report of the American College of Cardiology/American Heart Association Task Force on Clinical Practice Guidelines. *Circulation* 2017 **70** 252–289. (<https://doi.org/10.1016/j.jacc.2017.03.011>)
- Nishimura RA, Otto CM, Bonow RO, Carabello BA, Erwin JP, Guyton R, O'Gara PT, Ruiz CE, Skubas NJ, Sorajja P, *et al.* 2014 AHA/ACC Guideline for the management of patients with valvular heart disease. *Circulation* 2014 **129** e650. (<https://doi.org/10.1161/CIR.0000000000000029>)
- Gillam LD & Maricoff L. Hemodynamics in primary mitral regurgitation. *Circulation: Cardiovascular Imaging* 2018 **11** e007471. (<https://doi.org/10.1161/CIRCIMAGING.118.007471>)
- Hoepfer MM, Kramer T, Pan Z, Eichstaedt CA, Spiesshoefer J, Benjamin N, Olsson KM, Meyer K, Vizza CD, Vonk-Noordegraaf A, *et al.* Mortality in pulmonary arterial hypertension: prediction by the 2015 European pulmonary hypertension guidelines risk stratification model. *European Respiratory Journal* 2017 **50** 1700740. (<https://doi.org/10.1183/13993003.00740-2017>)
- Oudiz RJ. Death in pulmonary arterial hypertension. *American Journal of Respiratory and Critical Care Medicine* 2013 **188** 269–270. (<https://doi.org/10.1164/rccm.201305-0898ED>)
- Weitsman T, Weisz G, Farkash R, Klutstein M, Butnaru A, Rosenmann D & Hasin T. Pulmonary hypertension with left heart disease: prevalence, temporal shifts in etiologies and outcome. *American Journal of Medicine* 2018 **130** 1272–1279. (<https://doi.org/10.1016/j.amjmed.2017.05.003>)
- Simonneau G, Gatzoulis MA, Adatia I, Celermajer D, Denton C, Ghofrani A, Gomez Sanchez MA, Krishna Kumar R, Landberg M, Machado RF, *et al.* Updated clinical classification of pulmonary hypertension. *Journal of the American College of Cardiology* 2013 **62** D34. (<https://doi.org/10.1016/j.jacc.2013.10.029>)
- D'Alto M, Romeo E, Argiento P, D'Andrea A, Vanderpool R, Correria A, Bossone E, Sarubbi B, Calabrò R, Russo MG, *et al.* Accuracy and precision of echocardiography versus right heart catheterization for the assessment of pulmonary hypertension. *International Journal of Cardiology* 2017 **168** 4058–4062. (<https://doi.org/10.1016/j.ijcard.2013.07.005>)
- Rich JD, Shah SJ, Swamy RS, Kamp A & Rich S. Inaccuracy of Doppler echocardiographic estimates of pulmonary artery pressures in patients with pulmonary hypertension. *Chest* 2017 **139** 988–993. (<https://doi.org/10.1378/chest.10-1269>)
- Fisher MR, Forfia PR, Chamera E, Houston-Harris T, Champion HC, Girgis RE, Corretti MC & Hassoun PM. Accuracy of Doppler echocardiography in the hemodynamic assessment of pulmonary hypertension. *American Journal of Respiratory and Critical Care Medicine* 2009 **179** 615–621. (<https://doi.org/10.1164/rccm.200811-1691OC>)
- Greiner S, Jud A, Aurich M, Hess A, Hilbel T, Hardt S, Katus HA & Mereles D. Reliability of noninvasive assessment of systolic pulmonary artery pressure by Doppler echocardiography compared to right heart catheterization: analysis in a large patient population. *Journal of the American Heart Association: Cardiovascular and Cerebrovascular Disease* 2014 **3** e001103. (<https://doi.org/10.1161/JAHA.114.001103>)
- Roberts JD & Forfia PR. Diagnosis and assessment of pulmonary vascular disease by Doppler echocardiography. *Pulmonary Circulation* 2011 **1** 160–181. (<https://doi.org/10.4103/2045-8932.83446>)
- Magnino C, Omedè P, Avenatti E, Presutti D, Iannaccone A, Chiarlo M, Moretti C, Gaita F, Veglio F, Milan A, *et al.* Inaccuracy of right atrial pressure estimates through inferior vena cava indices. *American Journal of Cardiology* 2018 **120** 1667–1673. (<https://doi.org/10.1016/j.amjcard.2017.07.069>)
- Fei B, Fan T, Zhao L, Pei X, Shu X, Fang X & Cheng L. Impact of severe tricuspid regurgitation on accuracy of systolic pulmonary arterial pressure measured by Doppler echocardiography: analysis in an unselected patient population. *Echocardiography* 2017 **34** 1082–1088. (<https://doi.org/10.1111/echo.13555>)
- Mukerjee D, St. George D, Knight C, Davar J, Wells AU, Du Bois RM, Black CM & Coghlan JG. Echocardiography and pulmonary function as screening tests for pulmonary arterial hypertension in systemic sclerosis. *Rheumatology* 2004 **43** 461–466. (<https://doi.org/10.1093/rheumatology/keh067>)
- Caballero L, Kou S, Dulgheru R, Gonjilashvili N, Athanassopoulos GD, Barone D, Cardim N, Gomez de Diego JJ, Oliva MJ, Hagendorff A, *et al.* Echocardiographic reference ranges for normal cardiac Doppler data: results from the NORRE Study. *European Heart Journal: Cardiovascular Imaging* 2015 **16** 1031–1041. (<https://doi.org/10.1093/ehjci/jev083>)
- Schneider M, Pistrutto AM, Gerges C, Gerges M, Binder C, Lang I, Maurer G, Binder T & Goliash G. Multi-view approach for the diagnosis of pulmonary hypertension using transthoracic echocardiography. *International Journal of Cardiovascular Imaging* 2017 **34** 695–700. (<https://doi.org/10.1007/s10554-017-1279-8>)
- Rudski LG, Lai WW, Afilalo J, Hua L, Handschumacher MD, Chandrasekaran K, Solomon SD, Louie EK & Schiller NB. Guidelines for the echocardiographic assessment of the right heart in adults: a report from the American Society of Echocardiography. *Journal of the American Society of Echocardiography* 2017 **23** 685–713. (<https://doi.org/10.1016/j.echo.2010.05.010>)
- McQuillan BM, Picard MH, Leavitt M & Weyman AE. Clinical correlates and reference intervals for pulmonary artery systolic



- pressure among echocardiographically normal subjects. *Circulation* 2001 **104** 2797. (<https://doi.org/10.1161/hc4801.100076>)
- 23 Kitabatake A, Inoue M, Asao M, Masuyama T, Tanouchi J, Morita T, Mishima M, Uematsu M, Shimazu T, Hori M, *et al.* Noninvasive evaluation of pulmonary hypertension by a pulsed Doppler technique. *Circulation* 1983 **68** 302. (<https://doi.org/10.1161/01.CIR.68.2.302>)
  - 24 Howard LS, Grapsa J, Dawson D, Bellamy M, Chambers JB, Masani ND, Nihoyannopoulos P, Simon R & Gibbs J. Echocardiographic assessment of pulmonary hypertension: standard operating procedure. *European Respiratory Review* 2012 **21** 239–248. (<https://doi.org/10.1183/09059180.00003912>)
  - 25 Mallery JA, Gardin JM, King SW, Ey S & Henry WL. Effects of heart rate and pulmonary artery pressure on Doppler pulmonary artery acceleration time in experimental acute pulmonary hypertension. *Chest* 2018 **100** 470–473. (<https://doi.org/10.1378/chest.100.2.470>)
  - 26 Parasuraman S, Walker S, Loudon BL, Gollop ND, Wilson AM, Lowery C & Frenneaux MP. Assessment of pulmonary artery pressure by echocardiography: a comprehensive review. *International Journal of Cardiology: Heart and Vasculture* 2016 **12** 45–51. (<https://doi.org/10.1016/j.ijcha.2016.05.011>)
  - 27 Marra AM, Benjamin N, Ferrara F, Vriz O, D'Alto M, D'Andrea A, Stanziola AA, Gargani L, Cittadini A, Grünig E, *et al.* Reference ranges and determinants of right ventricle outflow tract acceleration time in healthy adults by two-dimensional echocardiography. *International Journal of Cardiovascular Imaging* 2017 **33** 219–226. (<https://doi.org/10.1007/s10554-016-0991-0>)
  - 28 Arkles JS, Opatowsky AR, Ojeda J, Rogers F, Liu T, Prassana V, Marzec L, Palevsky HI, Ferrari VA & Forfia PR. Shape of the right ventricular Doppler envelope predicts hemodynamics and right heart function in pulmonary hypertension. *American Journal of Respiratory and Critical Care Medicine* 2011 **183** 268–276. (<https://doi.org/10.1164/rccm.201004-0601OC>)
  - 29 Ryan T, Petrovic O, Dillon JC, Feigenbaum H, Conley MJ & Armstrong WF. An echocardiographic index for separation of right ventricular volume and pressure overload. *Journal of the American College of Cardiology* 1985 **5** 918–927. ([https://doi.org/10.1016/S0735-1097\(85\)80433-2](https://doi.org/10.1016/S0735-1097(85)80433-2))
  - 30 Austin C, Alassas K, Burger C, Safford R, Pagan R, Duello K, Kumar P, Zeiger T & Shapiro B. Echocardiographic assessment of estimated right atrial pressure and size predicts mortality in pulmonary arterial hypertension. *Chest* 2014 **147** 198–208. (<https://doi.org/10.1378/chest.13-3035>)
  - 31 Bossone E, D'Andrea A, D'Alto M, Citro R, Argiento P, Ferrara F, Cittadini A, Rubenfire M & Naeije R. Echocardiography in pulmonary arterial hypertension: from diagnosis to prognosis. *Journal of the American Society of Echocardiography* 2013 **26** 1–14. (<https://doi.org/10.1016/j.echo.2012.10.009>)
  - 32 Grapsa J, Pereira Nunes MC, Tan TC, Cabrita IZ, Coulter T, Smith BCF, Dawson D, Gibbs JSR & Nihoyannopoulos P. Echocardiographic and hemodynamic predictors of survival in precapillary pulmonary hypertension. Clinical perspective. *Circulation: Cardiovascular Imaging* 2015 **8** e002107. (<https://doi.org/10.1161/CIRCIMAGING.114.002107>)
  - 33 Lang RM, Badano LP, Mor-Avi V, Afilalo J, Armstrong A, Ernande L, Flachskampf FA, Foster E, Goldstein SA, Kuznetsova T, *et al.* Recommendations for cardiac chamber quantification by echocardiography in adults: an update from the American Society of Echocardiography and the European Association of Cardiovascular Imaging. *Journal of the American Society of Echocardiography* 2015 **28** 1.e14–39.e14. (<https://doi.org/10.1016/j.echo.2014.10.003>)
  - 34 Weatherald J, Boucly A, Chemla D, Savale L, Peng M, Jevnikar M, Jaïs X, Taniguchi Y, O'Connell C, Parent F, *et al.* Prognostic value of follow-up hemodynamic variables after initial management in pulmonary arterial hypertension. *Circulation* 2018 **137** 693–704. (<https://doi.org/10.1161/CIRCULATIONAHA.117.029254>)
  - 35 Abbas AE, Fortuin FD, Schiller NB, Appleton CP, Moreno CA & Lester SJ. A simple method for noninvasive estimation of pulmonary vascular resistance. *Journal of the American College of Cardiology* 2003 **41** 1021–1027. ([https://doi.org/10.1016/S0735-1097\(02\)02973-X](https://doi.org/10.1016/S0735-1097(02)02973-X))
  - 36 Berger M, Haimowitz A, Van Tosh A, Berdoff RL & Goldberg E. Quantitative assessment of pulmonary hypertension in patients with tricuspid regurgitation using continuous wave Doppler ultrasound. *Journal of the American College of Cardiology* 1985 **6** 359–365. ([https://doi.org/10.1016/S0735-1097\(85\)80172-8](https://doi.org/10.1016/S0735-1097(85)80172-8))
  - 37 Platts DG, Vaishnav M, Burstow DJ, Craig CH, Chan J, Sedgwick JF & Scalia GM. Contrast microsphere enhancement of the tricuspid regurgitant spectral Doppler signal: is it still necessary with contemporary scanners? *International Journal of Cardiology: Heart and Vasculture* 2017 **17** 1–10. (<https://doi.org/10.1016/j.ijcha.2017.08.002>)
  - 38 Rosenkranz S, Gibbs JS, Wachter R, De Marco T, Vonk-Noordegraaf A & Vachiery JL. Left ventricular heart failure and pulmonary hypertension. *European Heart Journal* 2015 **37** 942–954. (<https://doi.org/10.1093/eurheartj/ehv512>)
  - 39 D'Alto M, Romeo E, Argiento P, Pavelescu A, Melot C, D'Andrea A, Corraa A, Bossone E, Calabro R & Russo MG. Echocardiographic prediction of pre- versus postcapillary pulmonary hypertension. *Journal of the American Society of Echocardiography* 2017 **28** 108–115. (<https://doi.org/10.1016/j.echo.2014.09.004>)
  - 40 Opatowsky AR, Ojeda J, Rogers F, Prasanna V, Clair M, Moko L, Vaidya A, Afilalo J & Forfia PR. A simple echocardiographic prediction rule for hemodynamics in pulmonary hypertension clinical perspective. *Circulation: Cardiovascular Imaging* 2012 **5** 765.
  - 41 Ghoreishi M, Evans CF, DeFilippi CR, Hobbs G, Young CA, Griffith BP & Gammie JS. Pulmonary hypertension adversely affects short- and long-term survival after mitral valve operation for mitral regurgitation: Implications for timing of surgery. *Journal of Thoracic and Cardiovascular Surgery* 2011 **142** 1439–1452. (<https://doi.org/10.1016/j.jtcvs.2011.08.030>)
  - 42 Mentias A, Patel K, Patel H, Gillinov AM, Sabik JF, Mihaljevic T, Suri RM, Rodriguez LL, Svensson LG, Griffin BP, *et al.* Effect of pulmonary vascular pressures on long-term outcome in patients with primary mitral regurgitation. *Journal of the American College of Cardiology* 2016 **67** 2952–2961. (<https://doi.org/10.1016/j.jacc.2016.03.589>)

Received in final form 24 April 2018

Accepted 11 May 2018

Accepted Preprint published online 11 May 2018