

IMAGES AND VIDEOS

Sub-acute leaflet thrombosis: a reversible cause of aortic stenosis

Athina Chasapi MD, Adam Hobbs BSc, Theodore Velissaris MD FRSC CTh and Benoy N Shah MD MRCP FESC

Wessex Cardiac & Cardiothoracic Unit, University Hospital Southampton, Southampton, UK

Correspondence should be addressed to B N Shah: Benoy.Shah@uhs.nhs.uk

Summary

A 77-year-old male underwent elective bioprosthetic aortic valve replacement (23mm Carpentier-Edwards Perimount MagnaEase) for severe aortic stenosis. His pre-discharge transthoracic echocardiogram (TTE) was normal. He presented 9 days after surgery with dyspnea and fever. He was in sinus rhythm. Blood cultures were taken and he was commenced on empirical antibiotics for possible infective endocarditis (subsequently all negative). Repeat TTE showed a well-seated prosthesis without regurgitation but elevated gradients (peak/mean gradients 69/48mmHg respectively). Transoesophageal echocardiography (TOE) revealed marked thickening of the leaflets, without obvious vegetations (Fig. 1 and Videos 1, 2). The patient was diagnosed with subacute prosthetic valve thrombosis and was anticoagulated with apixaban. He underwent repeat TOE 3 months later, which

demonstrated thin, mobile valve leaflets with normalized transprosthetic gradients (Figs 2, 3 and Videos 3, 4). Thrombosis of a bioprosthetic valve is usually diagnosed in the early postoperative period, when endothelialisation of the suture zone is incomplete (1). Although previously considered rare (2), a recent observational study using cardiac CT imaging found an incidence of 4% (5/138) and 13% (101/752) in patients with surgical and transcatheter valves respectively (3). We have had another two cases of sub-acute bioprosthetic valve leaflet thrombosis in our centre this year, highlighting that this condition is not as rare as previously thought. Anticoagulation therapy – and not anti-platelet drugs – was associated with successful prevention and treatment of subclinical leaflet thrombosis (3). Indeed, American guidelines on valvular heart disease

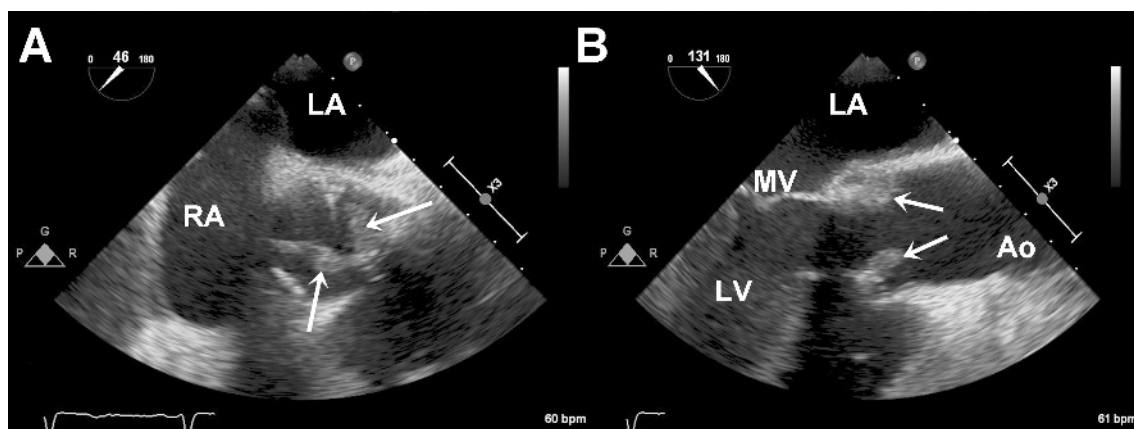


Figure 1 Mid-oesophageal short-axis (A) and long-axis (B) views of the bioprosthetic aortic valve demonstrating marked thickening of the leaflets (white arrows). Ao, aorta; LA, left atrium; LV, left ventricle; MV, mitral valve; RA, right atrium.

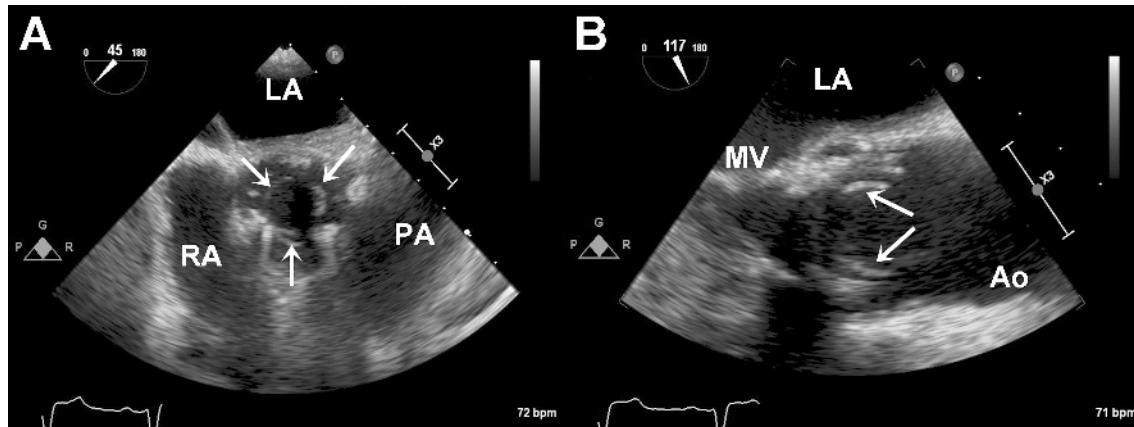


Figure 2

Mid-oesophageal short axis (A) and long axis (B) views of the bioprosthetic aortic valve on repeat TOE assessment, demonstrating thin and mobile valve leaflets (white arrows). (PA, pulmonary artery.)

give a Class IIb recommendation for a period (3–6 months) of formal anticoagulation after bioprosthetic AVR (4). Patients with established risk factors, including atrial fibrillation and a history of thromboembolic event, may have most to benefit from a brief period of routine post-operative anticoagulation (5).

Video 1

Mid-oesophageal aortic short-axis view revealing marked thickening of the bioprosthetic valve cusps (green arrows). LA, left atrium; PV, pulmonary valve; RA, right atrium. View Video 1 at <http://movie-usa.glencoesoftware.com/video/10.1530/ERP-18-0032/video-1>.

Video 2

Mid-oesophageal aortic long axis view revealing marked thickening of the bioprosthetic valve cusps (green arrows). View Video 2 at <http://movie-usa.glencoesoftware.com/video/10.1530/ERP-18-0032/video-2>.

Video 3

Mid-oesophageal aortic short axis view revealing normal appearances of the bioprosthetic valve cusps (green arrows). PA, pulmonary artery. View Video 3 at <http://movie-usa.glencoesoftware.com/video/10.1530/ERP-18-0032/video-3>.

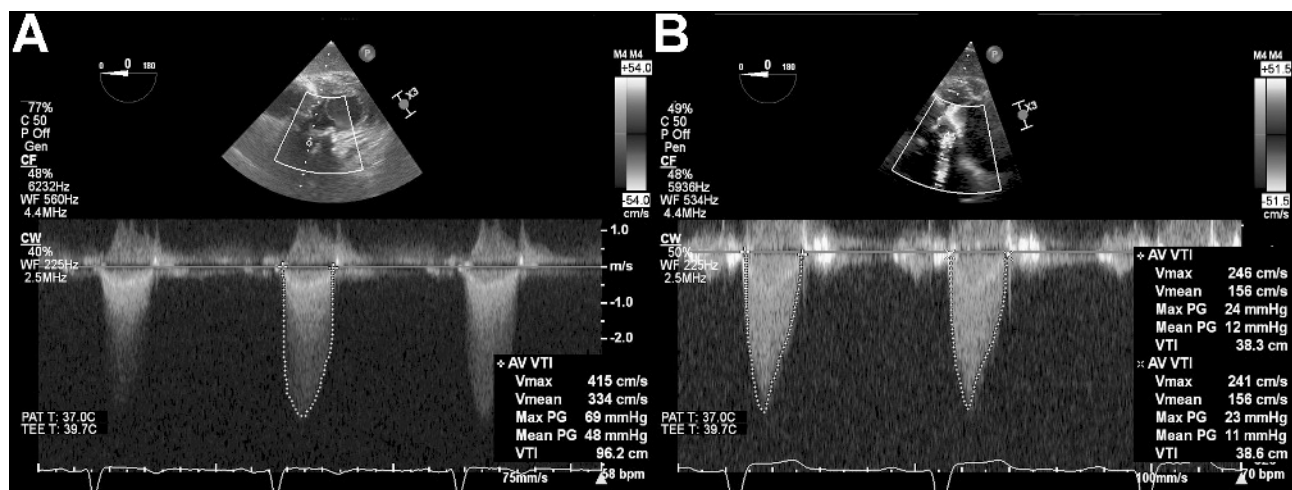


Figure 3

Continuous wave Doppler traces across the bioprosthetic valve before (A) and after (B) 3 months of anticoagulation therapy. Markedly elevated gradients across the valve returned to normal after resolution of valve leaflet thrombosis.

Video 4

Mid-oesophageal aortic long axis view revealing normal appearances of the bioprosthetic valve cusps (green arrows). View Video 4 at <http://movie-usa.glencoesoftware.com/video/10.1530/ERP-18-0032/video-4>.

Declaration of interest

The authors declare that there is no conflict of interest that could be perceived as prejudicing the impartiality of this article.

Funding

This work did not receive any specific grant from any funding agency in the public, commercial, or not-for-profit sector.

Patient consent

Written informed consent has been obtained from the patient.

Author contribution statement

B N S conceived the idea for the article, supervised both TOE procedures (2nd TOE performed by A H) and advised on patient management.

A C wrote the first draft of this article, which was subsequently revised by A H, B N S and T T V. T T V was responsible for the patient's care during the in-patient stay.

References

- 1 Roudaut R, Serri K & Lafitte S. Thrombosis of prosthetic heart valves: diagnosis and therapeutic considerations. *Heart* 2007 **93** 137–142. (<https://doi.org/10.1136/hrt.2005.071183>)
- 2 Puri R, Auffret V & Rodés-Cabau J. Bioprosthetic valve thrombosis. *Journal of the American College of Cardiology* 2017 **69** 2193–2211. (<https://doi.org/10.1016/j.jacc.2017.02.051>)
- 3 Chakravarty T, Søndergaard L, Friedman J, De Backer O, Berman D, Kofoed KE, Jilaihawi H, Shiota T, Abramowitz Y, Jørgensen TH, *et al.* Subclinical leaflet thrombosis in surgical and transcatheter bioprosthetic aortic valves: an observational study. *Lancet* 2017 **389** 2383–2392. ([https://doi.org/10.1016/S0140-6736\(17\)30757-2](https://doi.org/10.1016/S0140-6736(17)30757-2))
- 4 Nishimura RA, Otto CM, Bonow RO, Carabello BA, Erwin III JP, Guyton RA, O'Gara PT, Ruiz CE, Skubas NJ, Sorajja P, *et al.* 2014 ACC/AHA Guideline for the management of patients with valvular heart disease. *Journal of the American College of Cardiology* 2014 **63** e57–e185. (<https://doi.org/10.1016/j.jacc.2014.02.536>)
- 5 Cremer P & Barzilai B. Anticoagulation strategies after bioprosthetic valve replacement: what should we do? ACC 19.12.2016. Expert Analysis. (available at: <http://www.acc.org/latest-in-cardiology/articles/2016/12/19/08/44/anticoagulation-strategies-after-bioprosthetic-valve-replacement>)

Received in final form 1 June 2018

Accepted 6 June 2018

Accepted Preprint published online 12 June 2018