

RESEARCH

Handheld ultrasound to reduce requests for inappropriate echocardiogram (HURRIE)

Kawa Haji MBChB^{1,2,3}, Chiew Wong MBBS PhD^{2,3}, Christopher Neil MBBS PhD^{2,3}, Nicholas Cox MBBS², Andrew Mulligan MBBS², Leah Wright PhD^{1,2}, Sara Vogrin MBBS MBIostat³ and Thomas H Marwick MBBS PhD MPH^{1,2,3}

¹Baker Heart and Diabetes Institute, Melbourne, Australia

²Cardiology Department, Western Health, Melbourne, Australia

³Department of Medicine, University of Melbourne, Melbourne, Australia

Correspondence should be addressed to T H Marwick: tom.marwick@baker.edu.au

Abstract

Background: Handheld ultrasound could provide sufficient information to satisfy the clinical questions underlying 'rarely appropriate' echo requests, but there are limited data about its use as a gatekeeper to standard echocardiography. We sought to determine whether the use of handheld ultrasound could improve the appropriate use of echocardiography.

Method: A prospective study comparing handheld ultrasound strategy to standard echocardiography for studies deemed rarely appropriate, using a questionnaire based on appropriate use criteria was conducted across two hospitals, from October 2017 to April 2018.

Results: Groups undergoing Handheld ultrasound ($n = 76, 58$ (46.5–72.5) years, 53 males, 78% outpatients) and standard echocardiography ($n = 72, 61$ (49.0–71.5) years, 42 males, 76% outpatients) were comparable. There was a significant decrease in the time to scan from just over 1 month in standard group to a median of 12 days in handheld ultrasound group ($P < 0.001$). This difference was small for inpatients (from 1 day to a median of 10 min in handheld ultrasound, $P = 0.014$), but prominent in outpatients (from 1.5 months in the standard group to median of 2 weeks in the handheld ultrasound group, $P < 0.001$). There was no increase in the need for follow-up scan within 6 months and no significant differences in length of hospital stay for inpatients.

Conclusion: Handheld ultrasound can be an effective gatekeeper to standard echocardiography for requests deemed rarely appropriate, reducing time to echocardiography significantly and potentially decreasing the need for standard echocardiography by up to 20%.

Key Words

- ▶ handheld ultrasound
- ▶ rarely appropriate echocardiogram
- ▶ appropriate use
- ▶ appropriate use criteria

Introduction

The use of cardiovascular imaging continues to grow. In Australia, there is a 17-fold geographic variation in age-standardised imaging use, attributable more to ease of access and numbers of ordering physicians than it is to the prevalence of cardiovascular disease (1, 2, 3). Appropriate echocardiograms are those that are likely to

contribute to improving patients' clinical outcomes, and importantly, inappropriate use of echocardiography may potentially generate unwarranted costs to the healthcare system (4). Although in North America, the Appropriate Use Criteria (AUC) have been adopted to define when a test should be ordered (5), there are several limitations

to the use of an AUC process to control utilisation (6). Moreover, it is not clear that adoption of the AUC reduces utilisation.

There may be a technological solution to the problem of rarely appropriate (RA) echocardiograms. A simple screening algorithm can be used to identify inappropriate requests (7), and in these patients, a full 45–60-min echocardiogram can be circumvented by performance of a limited echocardiogram using handheld ultrasound (HHU). A previous report suggested that HHU could be used to reduce the time to echocardiography and cost compared to retrospective controls (8). We designed a prospective audit to address whether HHU could be applied as a gatekeeper to standard transthoracic echocardiography (StTTE) for rarely appropriate examinations, reducing numbers of StTTE performed and identifying important pathology that would have been missed if RA tests were cancelled.

Methods

Study design

In 2017, a policy of screening for appropriate use was introduced for all echocardiogram requests in patients above the age of 16 years referred for echocardiography in the Sunshine and Footscray Hospital campuses of Western Health (Melbourne, Australia). After they were evaluated for appropriateness, requests were assigned

to either a handheld device pathway or the standard echocardiography pathway. The pathway was determined by availability of appropriate resources for example appropriately trained operator or the appropriate outpatient list, available on 3 days of the week (Fig. 1). In this prospective audit, performed from October 2017 to April 2018, we also collected patient demographics and followed patients after 6 months. The protocol was approved by the Human Research Ethics Committee of Western Health.

Identification of RA echocardiograms

Patients were considered likely to have a RA echocardiogram if two of the four questions on a simplified questionnaire (9) (Appendix 1) were positive. The rationale of this is that it is too complex to incorporate >100 categories of AUC into day-to-day practice. The use of this simplified questionnaire identifies >80% of RA tests (9).

Echocardiography

Standard echocardiograms were performed using a standard protocol (10) using commercially available machines (Vivid e9, GE Medical Systems; Acuson SC2000, Siemens; EPIC 5, Philips Medical Systems).

The HHU examination was performed with an App-based ultrasound transducer with a compatible Android

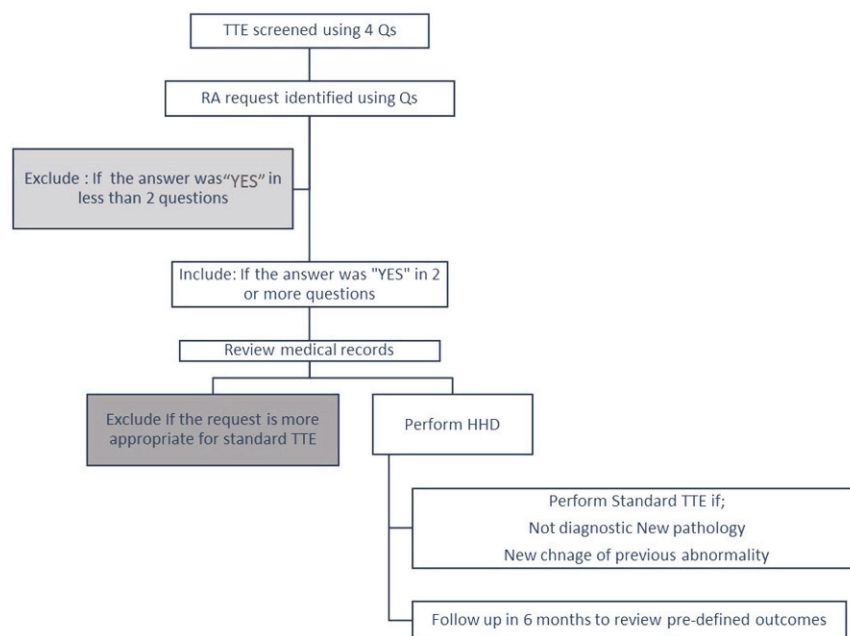


Figure 1
Study design.

Table 1 HHU protocol.

Parasternal long axis
2D images
Colour flow Doppler of valves
RV inflow view
2D images and colour
Parasternal short axis
Short-axis view at the aortic level and RVOT
Colour flow to evaluate pulmonic, aortic and tricuspid valve
Left ventricle at mitral valve (MV) level
Left ventricle at mid-level
Left ventricle at apex
Apical four chamber
2D imaging of the four chambers
Colour flow Doppler of valvular inflow and regurgitation
Colour flow of the interatrial septum
Apical five chambers
2D imaging
Colour flow Doppler of LVOT
Apical two chamber
2D imaging
Colour flow Doppler of MV
Apical long axis
2D imaging
Colour flow Doppler to visualise aortic and mitral forward and regurgitant flow
Subcostal view
Four chambers
2D imaging
Colour flow Doppler of at interatrial septum to assess for shunt
Inferior vena cava assessment
IVC images to evaluate size and dynamics
Suprasternal notch
Long axis view of the aortic arch
Other views as indicated for further clarification of assessment of specific pathologies

smart device (Lumify S4-1, Philips Medical Systems). The HHU study protocol involved only 2D and colour Doppler images across all standard echocardiographic views (Table 1). Spectral Doppler data were not part of the assessment as this feature is not available on the HHU. Disease severity was approximated from structural clues for stenotic lesions, and the size and duration of the colour jet (10). Linear or area measurements were made as appropriate.

All HHUs were performed by a sonographer specialised in echocardiography, cardiology trainee or cardiologist depending on availability. Images were wirelessly uploaded to the local echo database for reporting. All studies were reported by the cardiologist allocated for reporting studies for the day. A full study was requested if the HHU (1) was non-diagnostic, (2) identified a new abnormality or a change in a previously known abnormality.

Follow-up

Patients were followed up after 6 months to identify the need for repeat echocardiograms and other predefined outcomes.

Statistical analysis

Baseline characteristics and outcomes were compared for the HHU and StTTE groups. Continuous variables were compared using rank-sum test, while Fisher's exact test was used for categorical variables with a $P < 0.05$ considered statistically significant.

Results

Baseline characteristics

From 1877 echocardiography requests screened using the four appropriateness questions, 166 requests (8.8%) were deemed RA. These 166 were assigned either to HHU or StTTE, and studies were performed according to the availability of a suitably qualified person to perform the HHU and standard echocardiogram. After exclusion of 18 patients, who were unable to attend for echocardiography appointment, 148 patients (76 HHU and 72 StTTE) in whom RA tests had been requested were included. There were no significant differences in the clinical or the request characteristics of the two groups (Table 2). A cardiologist was the requesting physician in 43% of the HHU and 40% of StTTE examinations. The remaining requests in each arm were ordered by a combination of medical and surgical doctors. Routine cardiac follow-up in the absence of cardiovascular signs and symptoms was the most common reason for tests being labelled RA (Table 2).

Outcomes

There was a significant decrease in the time to scan from just over 1 month in standard group to a median of 12 days in HHU group ($P < 0.001$). This difference was small for inpatients (from 1 day to a median of 10 min in HHU, $P = 0.014$), but prominent in outpatients (from 1.5 months in the standard group to median of 2 weeks in the HHU group, $P < 0.001$) (Fig. 2).

Other outcomes are shown in Table 3. There was no statistical difference in finding new observations or in physician satisfaction between the HHU and stTTE group. There was no increase in a need for follow-up within 6 months, with around 15% of each group

Table 2 Baseline characteristics.

	HHU	stTTE	P
n	76	72	
Age (years), median (IQR)	58 (46.5–72.5)	61 (49.0–71.5)	0.38
Sex			
Female	23 (30%)	29 (40%)	0.18
Specialty			
Non-cardiology	43 (57%)	43 (60%)	0.70
Setting			
Outpatient	59 (78%)	55 (76%)	0.86
HTN	33 (43%)	30 (42%)	0.83
DM	22 (29%)	16 (22%)	0.35
Valvular disease	8 (11%)	6 (8%)	0.78
AF	10 (13%)	6 (8%)	0.43
IHD	19 (25%)	20 (28%)	0.70
Heart failure (systolic or diastolic)	30 (39%)	29 (40%)	1.00
Lung disease	10 (13%)	12 (17%)	0.65
Renal disease	20 (26%)	17 (24%)	0.85
Liver disease	3 (4%)	1 (1%)	0.62
Endocarditis study	7 (9%)	7 (10%)	1.00
No change in signs or symptoms	72 (95%)	70 (97%)	0.68
Routine	68 (89%)	64 (89%)	1.00
Echo in last year	28 (37%)	33 (46%)	0.27
Reason for inappropriateness			
Absence of new CV signs and symptoms + routine	40 (53%)	32 (44%)	0.32
Absence of new symptoms + routine + previous TTE	25 (33%)	30 (42%)	0.27
Suspected endocarditis + absence of new symptoms	5 (7%)	7 (10%)	0.56
Other combinations	6 (8%)	3 (4%)	0.50

requiring a follow-up. Length of stay for inpatients was not significantly different between the groups.

Discussion

The results of this study show that HHU can be used as a tool to reduce RA echocardiograms by significantly decreasing time to scan in both inpatient and outpatient settings without decreasing physician satisfaction or increasing the need in follow-up stTTE within 6 months. To our knowledge, this is the first prospective study to use HHU to reduce RA echocardiograms.

Handheld ultrasound

Echocardiography has been a major beneficiary of Moore's law (11) of increased processing power and memory with miniaturisation and falling cost. This is well exemplified by the most recent generation of handheld ultrasound (HHU) systems, which provide image quality analogous to a full-sized machine and are able to perform wireless transfer of images to a picture-archiving and communication system. Morphological, valvular and functional assessment of cardiac chambers by HHU has been shown to be analogous with stTTE (12, 13).

Apart from reliability, an HHU-based approach towards AUC also reduces cost and waiting time to scan. A previous cost analysis showed that a HHU-based approach would save up to \$72 USD per study (8). Decreasing costs have also been replicated for using HHU in other clinical settings by other groups (8, 14). Our study shows that a HHU-based approach can decrease time to scan in both inpatient and outpatient settings. Although the inpatient time to scan decrease was modest, the change in outpatient

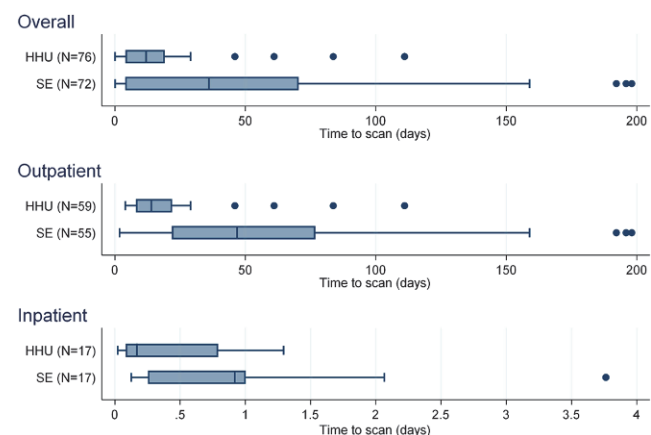


Figure 2
Time to scan.

Table 3 Outcomes.

	HHU (<i>n</i> = 76)	StTTE (<i>n</i> = 72)	P value
Time to scan (days) – overall, median (IQR)	12.0 (4.0, 19.1)	36.03 (3.93, 70.46)	<0.001
Time to scan (days) – Inpatient, median (IQR)	0.17 (0.08, 0.79) (<i>n</i> = 17)	0.92 (0.25, 1.00) (<i>n</i> = 17)	0.01
Time to scan (days) – Outpatient, median (IQR)	14.00 (8.00, 22.00) (<i>n</i> = 59)	46.78 (21.77, 76.84) (<i>n</i> = 55)	<0.001
Length of stay (days) – Inpatient, median (IQR)	13.0 (4.71, 17.63) (<i>n</i> = 17)	10.12 (6.63, 12.95) (<i>n</i> = 17)	0.8
New observation/or change in management	10 (13%)	8 (11%)	0.7
Physician satisfaction (1–5) 1 is least satisfied and 5 is most satisfied – inpatient (<i>n</i> = 17)			0.8
3	1 (6%)	0 (0%)	
4	3 (18%)	2 (12%)	
5	13 (76%)	15 (88%)	
Need for follow-up echocardiography	11 (14%)	11 (15%)	1.00

time to scan was significant (median time to scan 14 days with HHU vs 46 days for stTTE (Fig. 2)). This reduction in time to scan is not at the expense of repeating the stTTE after performing a HHU protocol, as there was no increase in the follow-up stTTE in 6 months.

Appropriate use

RA echocardiograms comprise 10–20% of echocardiogram requests (6, 15). While the exclusion of these studies has been considered as a means of improving efficiency, the reality is more complicated. First, clinicians arrange echocardiograms because of diagnostic uncertainty (16), and application of AUC to restrict test ordering is difficult to fit to the nuances of clinical presentation. Second, RA echocardiograms not uncommonly identify new and significant findings. Third, AUC are less firmly based on evidence than are the guidelines, and in some places contradict the guidelines (7). Indeed, there is not much evidence that AUC has engendered improvements in rates of inappropriate use (6).

As imaging continues to grow, the burden of the RA echocardiograms will increase and addressing the issue will become more urgent. The use of point-of-order radiology benefits management software based on the AUC have been proposed, but limits access to echocardiography in situations when it may be of clinical value (5, 17). The efficacy of education for reducing RA studies has been variable, and even if effective, is of uncertain durability.

The use of HHU as a replacement for a full echocardiogram seems to provide sufficient information to satisfy the referring physician, and follow-up echocardiography is not commonly required (14). The results of our study show that the use of HHU for RA studies decreases waiting times, while creating a safety net in picking up abnormalities which could have been missed if the test was cancelled. The new observations

that required a change in management occurred in 13% of HHU and 11% of stTTE. These results are concordant with the previous literature regarding new observations and abnormalities leading to change in management in RA studies (18, 19).

Limitations

The decision to undertake HHU in place of StTTE (when HHU resources were available) became a laboratory policy which this study sought to audit, so randomisation was not possible. Nonetheless, the groups were closely comparable. The average waiting time to scan might vary from one centre to another, so the external validity of these findings may vary.

Conclusion

Although echocardiography is a mature imaging modality, the development of new technologies continues to transform its clinical application. In this prospective comparison in of HHU to stTTE, HHU was a safe and reliable method for dealing with RA echocardiogram requests with less cost and shorter waiting times than laboratory echocardiograms.

Declaration of interest

The authors declare that there is no conflict of interest that could be perceived as prejudicing the impartiality of the research reported.

Funding

Supported in part by a Partnership grant from the National Health and Medical Research Council, Canberra, Australia. T H M is in receipt of research support from General Electric Medical Systems for an ongoing research study on the use of strain for the assessment of cardiotoxicity. No external funding was obtained for the study, which was performed with handheld systems loaned by Philips Medical Systems, Andover, MA.

References

- Fonseca R, Otahal P, Wiggins N & Marwick TH. Growth and geographical variation in the use of cardiac imaging in Australia. *Internal Medicine Journal* 2015 **45** 1115–1127. (<https://doi.org/10.1111/imj.12867>)
- Productivity Commission. *Impacts of Advances in Medical Technology in Australia*. Melbourne, Australia: Productivity Commission, Government of Australia Research Reports, 2005. (<https://doi.org/10.2139/ssrn.883533>)
- Australian Institute of Health and Welfare. *Health Expenditure Australia 2010–2011*. Canberra, Australia: AIHW, 2012. (available at: <https://www.aihw.gov.au/getmedia/c556b80f-5b15-4ef3-84a5-14ef8739c757/14373.pdf>)
- Douglas PS, Garcia MJ, Haines DE, Lai WW, Manning WJ, Patel AR, Picard MH, Polk DM, Ragosta M, Ward RP, *et al.* ACCF/ASE/AHA/ASNC/HFSA/HRS/SCAI/SCCM/SCCT/SCMR 2011 appropriate use criteria for echocardiography. A report of the American College of Cardiology Foundation Appropriate Use Criteria Task Force, American Society of Echocardiography, American Heart Association, American Society of Nuclear Cardiology, Heart Failure Society of America, Heart Rhythm Society, Society for Cardiovascular Angiography and Interventions, Society of Critical Care Medicine, Society of Cardiovascular Computed Tomography, and Society for Cardiovascular Magnetic Resonance endorsed by the American College of Chest Physicians. *Journal of the American College of Cardiology* 2011 **57** 1126–1166. (<https://doi.org/10.1016/j.jacc.2010.11.002>)
- Brindis RG, Douglas PS, Hendel RC, Peterson ED, Wolk MJ, Allen JM, Patel MR, Raskin IE, Hendel RC, Bateman TM, *et al.* ACCF/ASNC appropriateness criteria for single-photon emission computed tomography myocardial perfusion imaging (SPECT MPI): a report of the American College of Cardiology Foundation Quality Strategic Directions Committee Appropriateness Criteria Working Group and the American Society of Nuclear Cardiology endorsed by the American Heart Association. *Journal of the American College of Cardiology* 2005 **46** 1587–1605. (<https://doi.org/10.1016/j.jacc.2005.08.029>)
- Fonseca R, Negishi K, Otahal P & Marwick TH. Temporal changes in appropriateness of cardiac imaging. *Journal of the American College of Cardiology* 2015 **65** 763–773. (<https://doi.org/10.1016/j.jacc.2014.11.057>)
- Fonseca R & Marwick TH. Appropriateness and outcomes: is it time to adopt appropriate use criteria outside of North America? *Heart* 2014 **100** 357–358. (<https://doi.org/10.1136/heartjnl-2013-305273>)
- Pathan F, Fonseca R & Marwick TH. Usefulness of hand-held ultrasonography as a gatekeeper to standard echocardiography for ‘rarely appropriate’ echocardiography requests. *American Journal of Cardiology* 2016 **118** 1588–1592. (<https://doi.org/10.1016/j.amjcard.2016.08.027>)
- Fonseca R, Pathan F & Marwick TH. Development and validation of a screening tool for the identification of inappropriate transthoracic echocardiograms. *BMJ Open* 2016 **6** e012702. (<https://doi.org/10.1136/bmjopen-2016-012702>)
- Picard MH, Adams D, Bierig SM, Dent JM, Douglas PS, Gillam LD, Keller AM, Malenka DJ, Masoudi FA, McCulloch M, *et al.* American Society of Echocardiography recommendations for quality echocardiography laboratory operations. *Journal of the American Society of Echocardiography* 2011 **24** 1–10. (<https://doi.org/10.1016/j.echo.2010.11.006>)
- Moore GE. Cramming more components onto integrated circuits. In *Readings in Computer Architecture*, pp 56–59. San Francisco, CA, USA: Morgan Kaufmann Publishers Inc, 2000.
- Prinz C & Voigt JU. Diagnostic accuracy of a hand-held ultrasound scanner in routine patients referred for echocardiography. *Journal of the American Society of Echocardiography* 2011 **24** 111–116. (<https://doi.org/10.1016/j.echo.2010.10.017>)
- Breithardt OA. Hand-held ultrasound—the real stethoscope. *European Heart Journal Cardiovascular Imaging* 2015 **16** 471–472. (<https://doi.org/10.1093/ehjci/jeu320>)
- Kini V, Mehta N, Mazurek JA, Ferrari VA, Epstein AJ, Groeneveld PW & Kirkpatrick JN. Focused cardiac ultrasound in place of repeat echocardiography: reliability and cost implications. *Journal of the American Society of Echocardiography* 2015 **28** 1053–1059. (<https://doi.org/10.1016/j.echo.2015.06.002>)
- Gurzun MM & Ionescu A. Appropriateness of use criteria for transthoracic echocardiography: are they relevant outside the USA? *European Heart Journal Cardiovascular Imaging* 2014 **15** 450–455. (<https://doi.org/10.1093/ehjci/jet186>)
- Fonseca R, Jose K & Marwick TH. Understanding decision-making in cardiac imaging: determinants of appropriate use. *European Heart Journal Cardiovascular Imaging* 2018 **19** 262–268. (<https://doi.org/10.1093/ehjci/jex257>)
- Hendel RC. Utilization management of cardiovascular imaging pre-certification and appropriateness. *JACC: Cardiovascular Imaging* 2008 **1** 241–248. (<https://doi.org/10.1016/j.jcmg.2008.01.008>)
- Ward RP, Mansour IN, Lemieux N, Gera N, Mehta R & Lang RM. Prospective evaluation of the clinical application of the American College of Cardiology Foundation/American Society of Echocardiography Appropriateness Criteria for transthoracic echocardiography. *JACC: Cardiovascular Imaging* 2008 **1** 663–671. (<https://doi.org/10.1016/j.jcmg.2008.07.004>)
- Matulevicius SA, Rohatgi A, Das SR, Price AL, DeLuna A & Reimold SC. Appropriate use and clinical impact of transthoracic echocardiography. *JAMA Internal Medicine* 2013 **173** 1600–1607. (<https://doi.org/10.1001/jamainternmed.2013.8972>)

Received in final form 24 June 2019

Accepted 7 August 2019

Accepted Manuscript published online 8 August 2019