

CASE REPORT

Fulminant myocarditis: use of echocardiography from diagnosis to extracorporeal membrane oxygenation

Na Hyun Park, Hazem Lashin and Rosalba Spiritoso

Barts and The London NHS Trust, London, UK

Correspondence should be addressed to N H Park: na.park@nhs.net

Summary

Fulminant myocarditis can present with life-threatening arrhythmias and cardiogenic shock due to ventricular failure. The diagnosis of myocarditis usually requires histological and immunological information, as its aetiology may be infectious (viral or non-viral), autoimmune or drug related. The treatment of fulminant myocarditis depends on the underlying cause but usually includes high dose systemic steroids as well as physiological support. Veno-arterial extracorporeal membrane oxygenation (V-A ECMO) can be used to support patients as a bridge to recovery by supporting biventricular function and decompressing the heart. V-A ECMO carries risks and complications of its own such as thrombus formation or bleeding. Different diagnostic modalities, such as transthoracic echocardiogram (TTE) and transoesophageal echocardiogram (TOE), are central to the monitoring of progression of disease and recovery of heart function. This case highlights the importance of early recognition and early support with V-A ECMO in fulminant myocarditis, as well as the role of repeated echocardiography when weaning from physiological support.

Key Words

- ▶ echocardiography
- ▶ fulminant myocarditis
- ▶ transoesophageal echocardiography
- ▶ transthoracic echocardiography

Learning points:

- Myocarditis is a life-threatening condition and early recognition of cardiac failure can be assisted with a bedside echocardiogram.
- Extracorporeal membrane oxygenation is used as a bridging method of treatment for patients with cardiogenic failure in myocarditis but has its own risks related to anticoagulation and the procedure itself.
- There are currently no standardised guidelines of when to wean a patient off extracorporeal membrane oxygenation, but echocardiography acts as an important guide to detect complications as well as cardiac recovery.

Background

Myocarditis is an inflammatory disease of the myocardium that presents in a varying spectrum of severity and timing. Fulminant myocarditis can present with severe arrhythmias and cardiogenic shock due to ventricular

failure (1). Currently, V-A ECMO can be used as a bridging method to support these patients to recovery (1, 2). The role of echocardiography in diagnosing and management of myocarditis, especially in patients requiring V-A

ECMO is very important. It facilitates early identification of suitability, monitoring complications and clinical progress as well as using them to determine when to wean a patient off ECMO (1, 2, 3, 4).

Case presentation

A 48-year-old female, who recently returned from a holiday in Croatia, reported a 2-day history of coryzal symptoms and 1-day history of palpitations, dizziness and chest pain. Her past medical history included asthma and psoriasis. On presentation to the emergency department, she collapsed and was noted to be in polymorphic ventricular tachycardia, which developed into pulseless electrical activity (PEA) arrest requiring adrenaline and amiodarone, and three cycles of cardiopulmonary resuscitation (CPR). She was intubated and ventilated during the resuscitation.

Investigation

The ECG suggested nonspecific ST segment changes, life-threatening arrhythmia and Complete Heart Block. The serum troponin level was found to be raised at 1983 ng/mL.

A bedside transthoracic echocardiogram in the emergency department revealed biventricular failure with estimated left ventricular ejection fraction (LVEF) of 5–10%. A pericardial effusion was present (Figs 1 and 2) and there was septal wall thickening, suggesting myocardial oedema secondary to inflammation (Video 1). Arterial blood gas (ABG) measurement demonstrated a significant acidaemia of pH 7.30 and a raised lactate of 7.0 mmol/L.

Video 1

TTE parasternal short axis view at mid left ventricular cavity level demonstrating poor contractile function and the myocardium appears bright and thickened due to myocarditis. View Video 1 at <http://movie-usa.glencoesoftware.com/video/10.1530/ERP-20-0005/video-1>.

Treatment and outcome

The mobile ECMO team was contacted and were able to reach the referring hospital when the patient had achieved

return of spontaneous circulation within a timeframe that made her a good candidate for V-A ECMO.

Given the transient stability, the retrieving ECMO team had the opportunity to instigate a conference call attended by a multi-disciplinary team comprising of a cardiologist, cardiac surgeons and ECMO and cardiac intensive care consultants. The multi-disciplinary team discussed the pros and cons of initiating Extracorporeal Cardiac Life Support and given the high likelihood of reversibility, a unanimous decision was made to offer V-A ECMO. The consensus was also that the most likely aetiology of the cardiogenic shock was myocarditis.

Peripheral V-A ECMO cannulation was conducted in the ED department with ultrasound-guided cannulation was performed in the emergency department and cannulae position was confirmed with echocardiography. A 25 French drainage cannula was placed in the left femoral vein and a 15 French return cannula in the right femoral artery. The patient was established on V-A ECMO at blood flows of 4 L and sweep gas flow of 1 L. The procedure was uneventful, and the patient was transferred to our specialist cardiac centre immediately after. An angiogram was performed, which revealed unobstructed coronary arteries.

An intra-aortic balloon pump (IABP) was inserted (Fig. 3) as well as biventricular temporary pacing wires.

The patient was subsequently transferred to ICU and reviewed by the myocarditis team. High dose IV

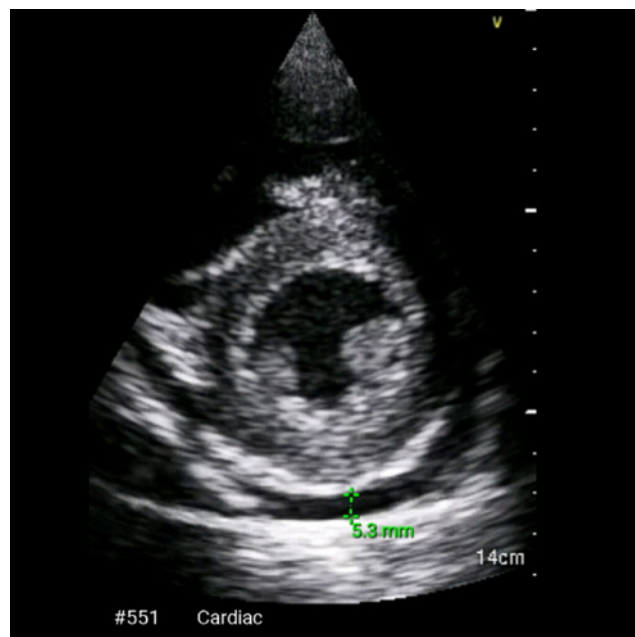


Figure 1
TTE parasternal short axis view on admission.

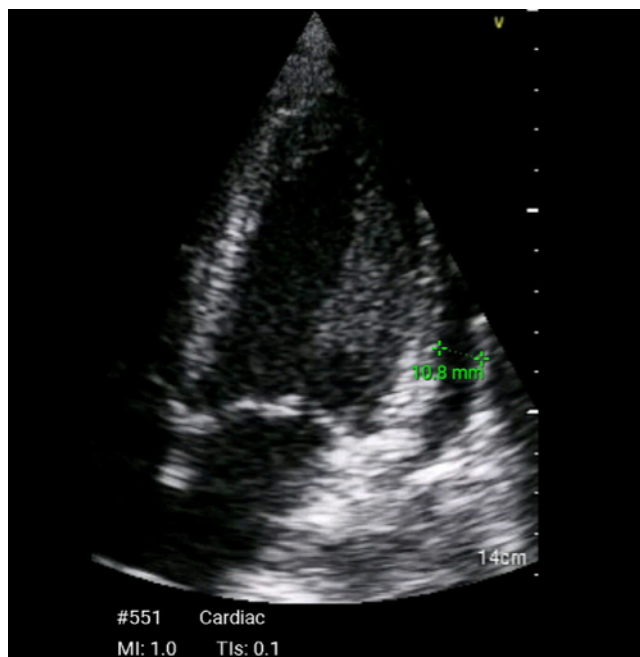


Figure 2

TTE apical four chamber view on admission- showing increased septal wall thickness, suggesting oedema secondary to the inflammatory process and pericardial effusion.

Methylprednisolone for fulminant myocarditis was commenced (methylprednisolone 1000 mg once a day for 3 days, followed by oral prednisone 1 mg/kg once a day with gradual weaning). Endomyocardial biopsy was not conducted at this time as it was deemed a high-risk procedure for bleeding due to anticoagulation on V-A ECMO. The patient remained stable and therefore a V-A ECMO weaning study was performed after 72 h.

In our department, a weaning study is conducted when a pulse pressure is greater than 15 mmHg and when the patient is on minimal inotropic and vasopressor requirements. The data collected during the weaning study include serial ABG measurements, continuous ECG monitoring via telemetry, invasive blood pressure, cardiac output monitoring as well as transoesophageal echocardiographic (TOE) assessment or transthoracic echocardiogram (TTE) where views are satisfactory. Our weaning study consists of three stages, each progressing to the next stage if cardiovascular stability is maintained by predetermined parameters. In each stage, we incrementally reduce the ECMO flow. For stage one, flow is reduced by 500 mL and left for 10 min. For stage two, we reduce the ECMO flow by 1 L for the next 10 min, and finally for stage three, we reduce the ECMO flow to

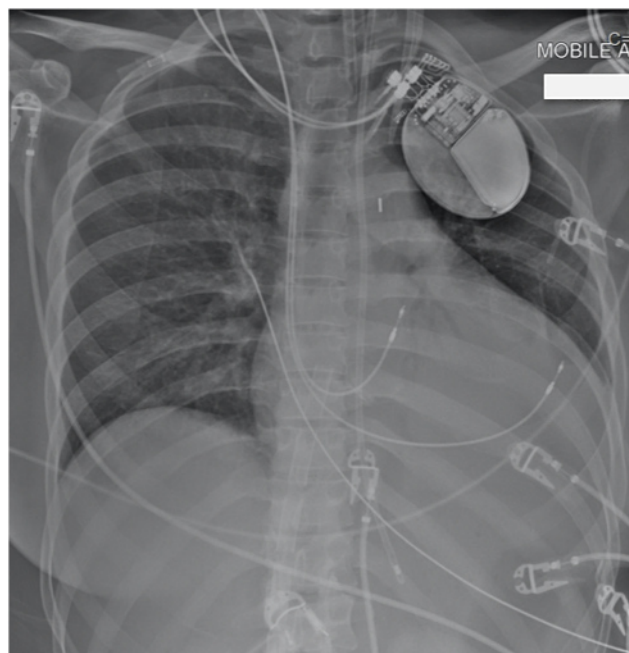


Figure 3

Chest X-ray showing intra-aortic balloon pump, temporary pacemaker, V-A ECMO drainage cannula.

1 L for 10 min. Between each stage, we assess whether the parameters meet the stopping criteria according to the data mentioned previously.

Our stopping criteria includes PCWP >15 mmHg or rise >5 mmHg, RAP >18 mmHg or rise >8 mmHg, Lactate >4 mmol/L, MAP <60 mmHg, rising inotropic requirements to maintain MAP >60 mmHg, significant hypoxia, arrhythmia or tachycardia of >120 b.p.m. If the weaning study is successful by fully progressing to stage three, ECMO flow is restored to >2 L and decannulation is planned at the earliest opportunity in theatre with support from our vascular surgery team for a femoral artery repair.

The echocardiography findings suggested good biventricular recovery on reduced ECMO flows. The left ventricular outflow tract velocity time integral (LVOT VTI) was 16 cm and left ventricular ejection fraction (LVEF) estimated and calculated by Simpson's method was 35%. The right ventricle was mildly impaired with overall good radial and longitudinal function by visual estimate; tricuspid annular plane systolic excursion (TAPSE) was >16 mm. ABG and haemodynamic variables remained stable during the weaning study.

Unfortunately, a large thrombus attached to the tip of the drainage cannula extending into the right atrium (RA) was noted (Video 2).

Video 2

TTE subcostal inferior vena cava view demonstrating V-A ECMO drainage cannula (left arrow) in the inferior vena cava extending into the right atrium with thrombus attached to cannula tip (right arrow). View Video 2 at <http://movie-usa.glencoesoftware.com/video/10.1530/ERP-20-0005/video-2>.

The decision was made to increase anticoagulation targets and plan for decannulation and femoral artery repair at the earliest possible time.

The following day, she was taken to theatre for a final TOE guided weaning study and decannulation. The TOE exam identified new onset of right ventricular dysfunction with significantly reduced right ventricular longitudinal and radial function. There was minimal TAPSE visualised, unfortunately, a measurement was not formally documented. The left ventricular outflow tract velocity time integral (LVOT VTI) was 10.1 cm (Fig. 4) drastically lower compared to the previous day (LVOT VTI 16 cm).

Due to these TOE findings, the decannulation procedure was postponed allowing time to the right ventricle to recover. A pulmonary artery catheter was not inserted due to the presence of the large thrombus in right atrium, measuring 3.3 cm² as assessed by tracing the thrombus in the transthoracic apical four chamber view.

It was presumed that the cause of the new onset of acute right heart failure might have been due to micropulmonary emboli causing increased pulmonary vascular resistance and acute right ventricular failure. The thrombus appeared to be very friable and changing in size and shape (Fig. 5 and Video 3). A CT of pulmonary arteries

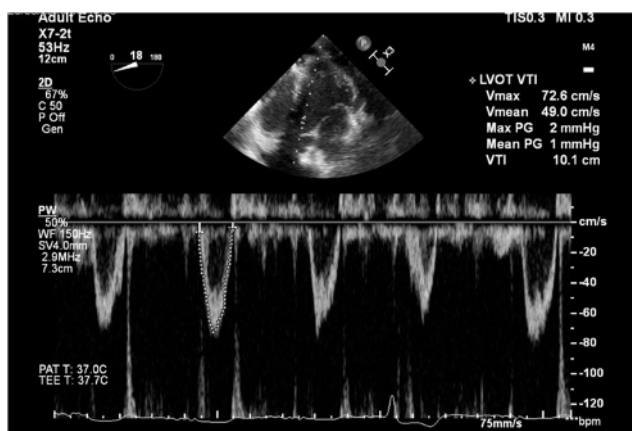


Figure 4

TOE deep transgastric long axis view on day 4 on V-A ECMO – LVOT VTI 10.1 cm.

was discussed; however, given the rapid improvement over the following hours and no respiratory deterioration whatsoever, the decision was made not to expose the patient to critical transfer as this would not have changed the management.

Video 3

TTE apical four chamber view zoomed on the right atrium. Thrombus adherent to the inter-atrial septum on the right atrium. View Video 3 at <http://movie-usa.glencoesoftware.com/video/10.1530/ERP-20-0005/video-3>.

She remained on V-A ECMO and was commenced on pharmacological inotropic support with milrinone (phosphodiesterase 3 inhibitor) and epoprostenol nebulisers to reduce right ventricular afterload. The right ventricle progressively improved and partial resolution of the RA thrombus was noted in consecutive TTE images (Fig. 6).

After a repeated weaning study, V-A ECMO was successfully withdrawn on day 7. The patient experienced no other complications from V-A ECMO. The IABP was removed 2 days after ECMO decannulation. Repeat TTE on day 11 revealed improved left ventricular function as suggested by visual assessment, calculated LVEF of 30–35% and LVOT VTI of 13.2 cm (LVOT VTI on day 4 was 10.1 cm as per Fig. 6).

The patient required prolonged respiratory wean and prolonged physical rehabilitation due to deconditioning secondary to her long ICU stay. After decannulation, a permanent Cardiac Resynchronisation Therapy device with Defibrillator (CRT-D) was inserted. She was stepped down to the ward on her 27th day of admission,

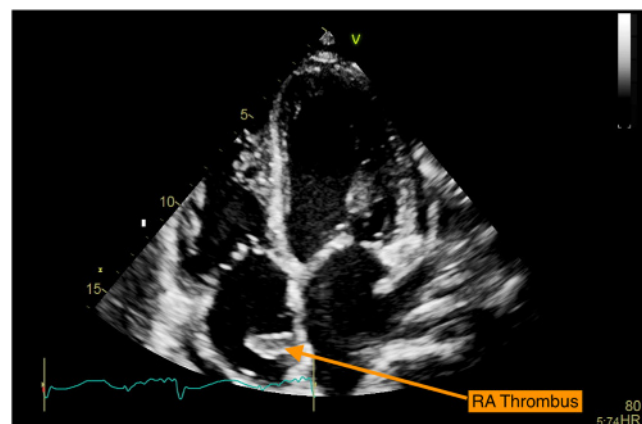


Figure 5

TTE apical four chamber view on day 3 – large thrombus in right atrium.

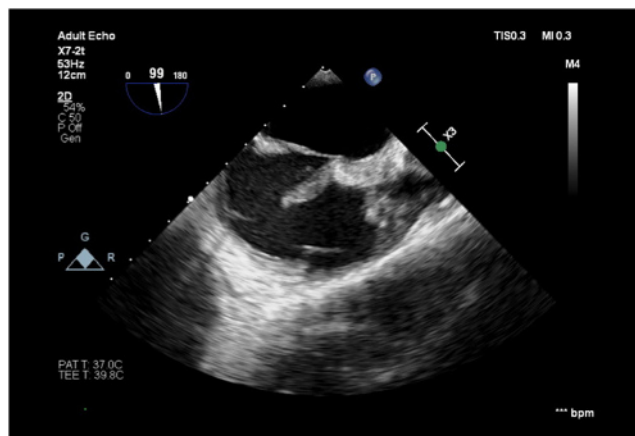


Figure 6
TOE mid-oesophageal bicaval view – thrombus in right atrium.

where immunosuppression therapy was continued on the wards. An endomyocardial biopsy was conducted during her stay in the wards, but unfortunately showed non-diagnostic tissue characterisation. After discussion, the most likely cause was thought to be inflammatory myocarditis rather than infiltrative myocarditis. Repeat transthoracic echocardiogram continued to show impaired left ventricular function (Video 4). As Giant cell myocarditis remained a possibility, treatment with Ciclosporin continued. She was discharged home on day 78 with weaning doses of immunosuppression. Her immunological and microbiology investigations, including a virology screen, were negative.

Video 4

TTE parasternal long axis view after decannulation demonstrating ongoing impaired contractile function. The myocardium appears bright and thickened due to myocarditis. View Video 4 at <http://movie-usa.glencoesoftware.com/video/10.1530/ERP-20-0005/video-4>.

Discussion

This case demonstrates the complex journey of fulminant myocarditis from presentation to discharge. Diagnosis of myocarditis is complex and involves endomyocardial biopsy, virology, histology, immunological, microbiology results (1), which takes time and planning. We note that even after the patient was stabilised, there were no positive findings in our patient's case, highlighting the complexity of diagnosis in an acute presentation of fulminant myocarditis.

This case also highlights the use of echocardiography in cardiogenic shock. Echocardiography is a point of care tool which is widely used to aid diagnosis in cardiac pathology (3). In our case, it facilitated the identification of acute biventricular failure and features suggesting a diagnosis of fulminant myocarditis. This expedited the decision to support the patient with V-A ECMO as a bridging method to treatment. Without this modal of imaging, the decision to refer would have been difficult.

Literature suggests echocardiography also provides guidance during the process of ECMO cannulation, identifying the presence of complications and assessing readiness for weaning (3). In our case, the echocardiography study done on day 3 allowed the identification of the RA thrombus, which prompted the decision to increase the anticoagulation level, reducing the risk of increasing thrombus size and pulmonary embolism.

As for weaning, the timing and strategies of weaning from ECMO vary between centres with no standard or guidelines (4, 5). The term weaning is also defined differently dependent on centres and does not translate to mortality rates in a longer term, as some studies suggest mortality in the first 48 h after explantation (5, 6), whilst others suggest remaining off cardiogenic support for the following 30 days after explantation (4). To date, there is very little literature with regards to ideal weaning strategies and most reliable predictors of successful weaning (4). The decision of weaning and removal of V-A ECMO is dependent on multiple findings including, echocardiography, haemodynamic parameters, inotropic support, appropriate biochemistry markers and assessment during a weaning study (5). Of these, echocardiography studies are able to assess cardiac function in real-time as scanning is taking place. Once all these factors are taken into consideration, then planning of decannulation takes place (5). In our case, the echocardiogram done on the weaning day allowed the identification of impaired right ventricular (RV) function and therefore postponed the V-A ECMO removal. Without it, the patient would have been decannulated, and this could have led to mortality due to right ventricular failure. Reports suggest that the current practice in many centres is the conduct of daily transthoracic/transoesophageal echocardiograms to determine weaning times (6). It is also used to identify complications such as a thrombus in the LV of non-ejecting hearts. However, clear guidance is lacking as to how often echocardiography should be performed, and which exact indices will indicate readiness for weaning (7, 8). Increased duration of ECMO is associated with

increased complication and mortality rates (5, 8). An optimal weaning timeline is desirable and developing evidence-based guidelines for this process may facilitate this (5, 8).

Declaration of interest

The authors declare that there is no conflict of interest that could be perceived as prejudicing the impartiality of this case report.

Funding

This work did not receive any specific grant from any funding agency in the public, commercial or not-for-profit sector.

Patient consent

Written informed consent for publication of their clinical details and/or clinical images was obtained from the patient.

Author contribution statement

Na Park wrote the case report, gathered the figures and obtained written consent from the patient. Hazem Lashin obtained the echocardiogram images and oversaw the content of the case report. Rosalba Spiritoso supervised this case report and performed oversight of each draft as well as the figures. All three physicians had direct involvement in patient care.

References

- 1 Seif E, Chen L & Goldman B. Fulminant myocarditis: a review of the current literature. *US Cardiology Review* 2018 **12** 13–16. (<https://doi.org/10.15420/usc.2017:31:1>)
- 2 Doufle G, Roscoe A, Billia F & Fan E. Echocardiography for adult patients supported with extracorporeal membrane oxygenation. *Critical Care* 2015 **19** 326. (<https://doi.org/10.1186/s13054-015-1042-2>)
- 3 Veronese G, Ammirati E, Cipriani M & Frigerio M. Fulminant myocarditis: characteristics, treatment, and outcomes. *Anatolian Journal of Cardiology* 2018 **19** 279–286. (<https://doi.org/10.14744/AnatolJCardiol.2017.8170>)
- 4 Aissaoui N, Luyt CE, Leprince P, Trouillet JL, Leger P, Pavie A, Diebold B, Chastre J & Combes A. Predictors of successful extracorporeal membrane oxygenation (ECMO) weaning after assistance for refractory cardiogenic shock. *Intensive Care Medicine* 2011 **37** 1738–1745. (<https://doi.org/10.1007/s00134-011-2358-2>)
- 5 Pappalardo F, Pieri M, Arnaez Corada B, Ajello S, Melisurgo G, De Bonis M & Zangrillo A. Timing and strategy for weaning from venoarterial ECMO are complex issues. *Journal of Cardiothoracic and Vascular Anesthesia* 2014 **29** 906–911. (<https://doi.org/10.1053/j.jvca.2014.12.011>)
- 6 Ortuno S, Delmas C, Diehl JL, Bailleul C, Lancelot A, Naili M, Cholley B, Pirracchio R & Aissaoui N. Weaning from veno-arterial extra-corporeal membrane oxygenation: which strategy to use? *Annals of Thoracic Surgery* 2019 **8** E1–E8. (<https://doi.org/10.21037/acs.2018.08.05>)
- 7 Luo XJ, Wang W, Hu SS, Sun HS, Gao HW, Long C, Song YH & Xu JP. Extracorporeal membrane oxygenation for treatment of cardiac failure in adult patients. *Interactive Cardiovascular and Thoracic Surgery* 2009 **9** 296–300. (<https://doi.org/10.1510/icvts.2008.197681>)
- 8 Smedira NG, Moazami N, Golding CM, McCarthy PM, Apperson-Hansen C, Blackstone EH & Cosgrove III DM. Clinical experience with 202 adults receiving extracorporeal membrane oxygenation for cardiac failure: survival at five years. *Journal of Thoracic and vascular Surgery* **122** 92–102. (<https://doi.org/10.1067/mtc.2001.114351>)

Received in final form 27 April 2020

Accepted 20 July 2020

Accepted Manuscript published online 21 July 2020