

IMAGES AND VIDEOS

Cor triatriatum or divided left atrium presenting as mitral stenosis in an adult patient

Alfonso Pecoraro MBChB(US) FCP(SA) M.Med(US) Cert Cardio Phys(SA)¹,
Jacques Janson MBChB MMed(Thor)(Stell) FCS(Thor)(SA) PhD² and Jacob Daniel Cilliers MBChB(US) DipHIV(SA)¹

¹Tygerberg Hospital, Cape Town, South Africa

²Division of Cardiothoracic Surgery, Tygerberg Hospital, Cape Town, South Africa

Correspondence should be addressed to J D Cilliers: jdcilliers123@gmail.com

Summary

A 26-year-old male patient presented to the hospital with a 2-month history of progressive dyspnoea. He denied chest pain, coughing, orthopnoea, paroxysmal nocturnal dyspnoea, syncope or pre-syncope.

He had no other significant comorbidities and he was not on any chronic medication.

His cardiovascular examination revealed an undisplaced apex beat with a parasternal heave and a loud second heart sound (P2) suggestive of pulmonary hypertension. On auscultation, the first heart sound was normal with a loud second heart sound and a

diastolic rumble. Given these findings, a clinical diagnosis of severe mitral stenosis with pulmonary hypertension was made. ECG was atypical for mitral stenosis, it revealed a dilated LA with left axis deviation due to a left anterior hemiblock. No features of right ventricular hypertrophy was noted.

To our surprise, echocardiographic evaluation (Figs 1 and 2) revealed a primum ASD with the normal function of the left and right atrioventricular (AV) valve. A left-sided supra-valvular ridge or divided left atrium was identified with peak and mean gradients of 43/21 mmHg, respectively (Fig. 3). Video 1 is an apical four-chamber view of the defect, pre-operatively.

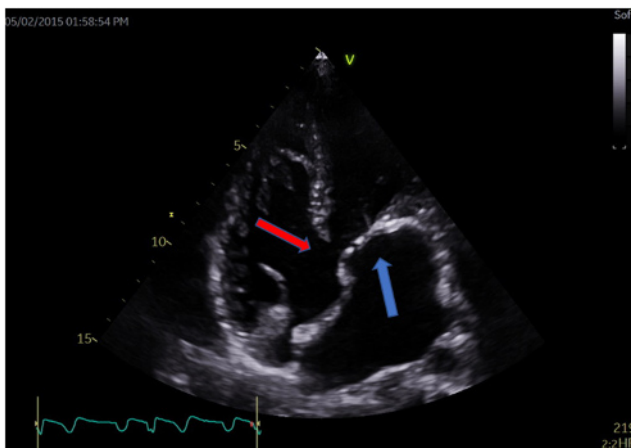


Figure 1
Apical four-chamber view, demonstrating a primum ASD, with the absence of an apical offset of the right side AV valve (red arrow). In addition, supra-valvular obstruction is seen, proximal to the left-sided AV valve (blue arrow).

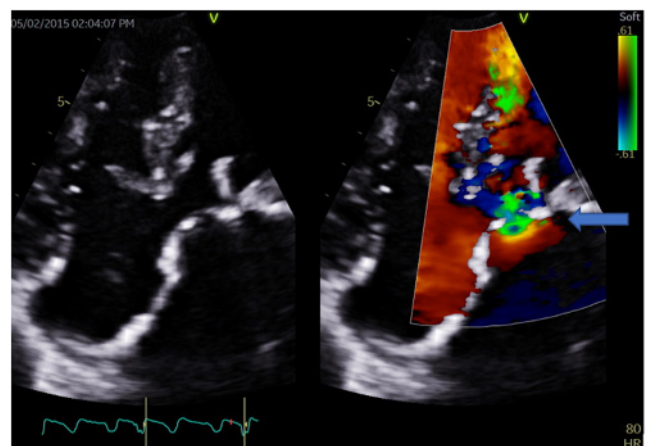


Figure 2
Apical four-chamber view with color, demonstrating turbulent flow at the level of the supra-valvular obstruction (arrow).

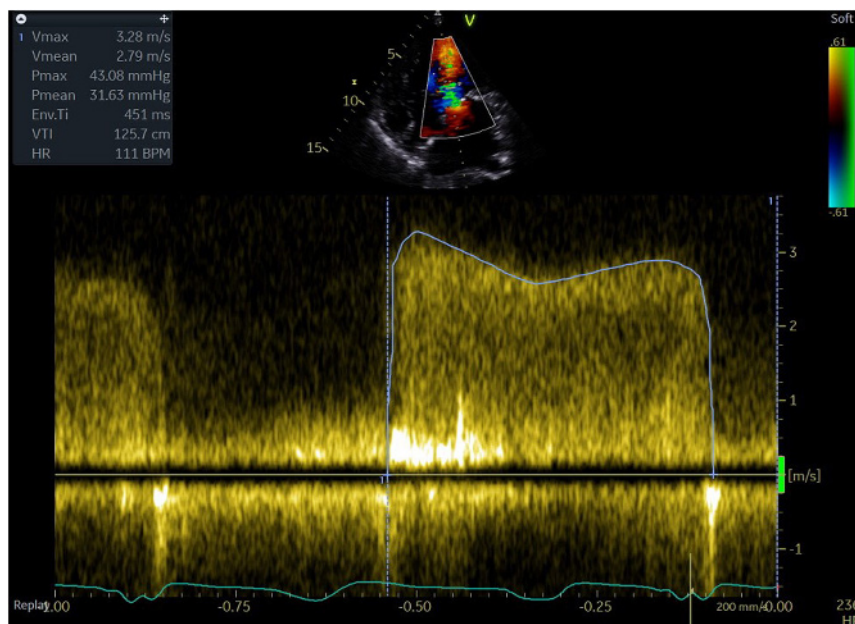


Figure 3
Apical four-chamber view with continuous wave
Doppler (CW), demonstrating.

Video 1

Apical four-chamber, pre-operatively. View Video 1 at <http://movie-usa.glencoesoftware.com/video/10.1530/ERP-20-0016/video-1>.

Video 2

Apical four-chamber, post-operative result. View Video 2 at <http://movie-usa.glencoesoftware.com/video/10.1530/ERP-20-0016/video-2>.

The primum ASD was repaired with a pericardial patch and the supraventricular ridge causing left ventricular inflow obstruction was resected.

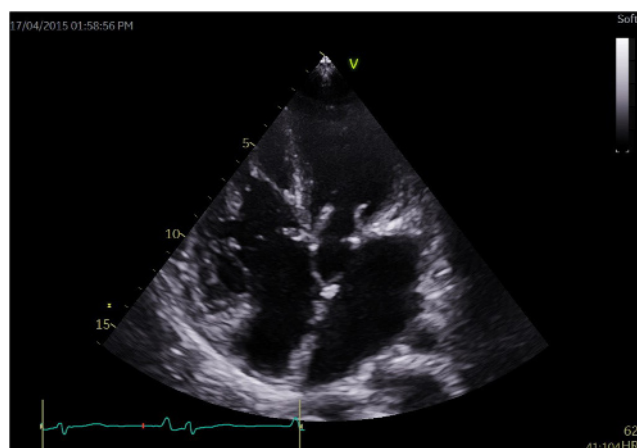


Figure 4
Post-operative apical four-chamber view, demonstrating repair primum
ASD, with no supralvalvular obstruction.

The patient was discharged 5 days after surgery and has remained asymptomatic during routine follow up. Post-operative echocardiography revealed successful surgery with normal diastolic gradients of the left AV valve (Fig. 4). Video 2 is an apical four-chamber of the post operative result.

AVSD is a well-known congenital abnormality affecting 1 in 2120 live births. To the best of our knowledge, this is only the second case description of an AVSD with a divided left atrium or cor triatriatum sinister (1).

Echocardiography plays an integral part in the diagnosis of complex congenital heart disease. A systematic approach to performing echocardiography in patients known with congenital heart disease is essential for all adult cardiologists.

Declaration of interest

The authors declare that there is no conflict of interest that could be perceived as prejudicing the impartiality of this article.

Funding

This work did not receive any specific grant from any funding agency in the public, commercial or not-for-profit sector.

Patient consent

The patient lived in an informal settlement and we were unable to reach him or any of his family members, as there was no contact number given by the patient on admission and the patient was no longer living at the address given.

Author contribution statement

Alfonso Pecoraro: primary physician (Cardiologist) involved in the case.
 Jacques Janson: performed surgical repair of the defect.

References

- 1 Reddy TD, Valderrama E & Bierman FZ. Images in cardiology. Atrioventricular septal defect with cor triatriatum. *Heart* 2002 **87** 215. (<https://doi.org/10.1136/heart.87.3.215>)

Received in final form 8 August 2020

Accepted 9 September 2020

Accepted Manuscript published online 9 September 2020