

## RESEARCH

# Prognostic value of resting myocardial contrast echocardiography: a meta-analysis

Lijun Qian<sup>1</sup>, Feng Xie<sup>2</sup>, Di Xu<sup>1</sup> and Thomas R Porter<sup>2</sup>

<sup>1</sup>Department of Geriatrics, The First Affiliated Hospital of Nanjing Medical University, Nanjing, China

<sup>2</sup>Department of Internal Medicine, Section of Cardiology, University of Nebraska Medical Center, Omaha, Nebraska, USA

Correspondence should be addressed to D Xu or T R Porter: [xudi@jsph.org.cn](mailto:xudi@jsph.org.cn) or [trporter@unmc.edu](mailto:trporter@unmc.edu)

## Abstract

**Background:** Resting myocardial perfusion (MP) and wall motion (WM) imaging during real-time myocardial contrast echocardiography (MCE) improves the detection of coronary artery disease (CAD). However, its prognostic role in different clinical settings (emergency department and outpatient setting) remains unclear.

**Methods:** A systematic search in PubMed and Embase databases, and the Cochrane library, was conducted to evaluate the role of resting MP and WM in predicting major adverse cardiac events (MACE), including death, nonfatal myocardial infarction (NFMI) and urgent revascularization in patients presenting to either outpatient clinics or emergency departments with suspected symptomatic CAD. Summary receiver operating characteristic (SROC) curves, sensitivity and specificity plots were applied to assess diagnostic performance using RevMan 5.3.

**Results:** Seven studies met criteria, including 3668 patients (six with follow up ranging from 2 days to 2.6 years). The Relative Risk (RR) for predicting MACE in patients with both abnormal resting MP and WM was 6.1 (95% CI, 5.1–7.2) and 14.3 (95% CI, 10.3–19.8) for death/NFMI, when compared to normal resting MP and WM patients. Having both abnormal resting MP and WM was also more predictive of MACE (RR, 1.7; 95% CI 1.5–1.9) and death/NFMI (RR, 2.2; 95% CI, 1.8–2.7) when compared to abnormal WM with normal resting MP.

**Conclusion:** In this meta-analysis of both ED and outpatient clinic presentations for suspected CAD, having both a resting regional MP and WM abnormality identifies the highest risk patient for adverse events.

## Key Words

- ▶ myocardial contrast echocardiography
- ▶ prognosis
- ▶ coronary artery disease

## Introduction

Suspected symptomatic coronary artery disease (CAD) is a common reason for referral to an emergency department (ED) or outpatient clinic (1). Although standardized clinical risk scores utilizing EKG and biomarker data are commonly applied in the ED setting (2, 3), up to 7% of those discharged from the ED still subsequently have acute coronary events (ACS) (4). The EKG in the majority of symptomatic patients is nondiagnostic, and although

newer high sensitivity troponin assays are being utilized to improve disease detection, they may still be normal on the initial sample or false positive for a wide variety of associated co-morbidities (5).

Resting myocardial perfusion (MP) and wall motion (WM) have been utilized with myocardial contrast echocardiography (MCE) to improve the sensitivity of 2D echocardiography for detecting symptomatic

coronary artery disease (CAD) in both the ED as well as outpatient referral setting (6, 7, 8, 9, 10, 11, 12, 13, 14). Furthermore, when utilizing real-time MCE with very low mechanical index imaging and brief high mechanical index impulses to clear myocardial contrast, it is possible to detect subendocardial WM abnormalities even when transmural wall thickening appears normal (6). This has further improved the sensitivity of resting WM analysis with echocardiography in predicting outcome (7). In the evaluation of chest pain or suspected CAD, the detection of a resting regional WM abnormality has been shown to predict adverse outcomes (7, 8, 9, 10, 11, 12, 13, 14). The resting regional WM abnormality may occur with either normal or abnormal MP, since MP may have returned to normal if reperfusion has occurred following an ischemic event (myocardial stunning). A combination of both abnormal regional WM (WMA) and abnormal MP (MPA) in this setting has been considered the highest risk for adverse events, as it may identify a persistent thrombotic occlusion. The objective of this meta-analysis was to summarize the available evidence regarding the role of resting MCE in predicting subsequent major adverse cardiac events in patients with suspected symptomatic CAD and a nondiagnostic ECG. Patients presenting in both an acute setting (ED) or less urgent (outpatient evaluation of suspected symptomatic CAD) were included in this analysis.

## Methods

### Study selection

We followed the Preferred Reporting Items for Systematic Reviews and Meta-Analyses guidelines for systematic reviews of observational and diagnostic studies. A comprehensive literature search was performed throughout PubMed and Embase databases, and the Cochrane library, with the following terms and key words: 'contrast', 'echocardiography', 'perfusion', 'chest pain' and 'acute coronary syndrome'. Searches were completed by November 2019.

### Selection criteria

All the selected studies were initially screened for relevance at the abstract level. The inclusion criteria were as follows: (1) population: suspected symptomatic CAD and no ST-segment elevation in either an ED setting or echocardiography lab; (2) utilization of MCE;

(3) examining both resting WM and MP analysis; and (4) diagnostic or clinical outcomes. We included peer-reviewed studies that assessed the diagnostic accuracy of qualitative MP and WM analysis in patients with suspected symptomatic CAD and nondiagnostic ST findings. Patients undergoing resting MP and WM analysis prior to planned stress echocardiography were included, if the predictive value of resting MP and WM analysis were analyzed separately from stress data. The end point included (1) the incremental effect resting MP and WM analysis in detecting an ACS and (2) the effect of resting MP and WM analysis in predicting longer term major adverse cardiac events (MACE), including the separate detection of nonfatal myocardial infarction (NFMi) and death.

### Data collection

Two investigators performed eligibility assessment with a standardized data extraction individually and another reviewer checked the data. Basic information was extracted as follows: study name, patient number, study design, enrolling time, length of follow-up, age, gender, diagnosis of patients, the presence of coronary risk factors (diabetes mellitus, hypertension, dyslipidemia, and family history of coronary artery disease), and smoking status. Additionally, technical characteristics of resting MCE, criteria of abnormal MCE, reference standard and end point definition were retrieved from the articles.

### Quality assessment

Two reviewers evaluated the risk of bias with the Cochrane Collaboration's tool (RevMan 5.3) in the included trials. The publication bias, including the risk of selection bias, performance bias, detection bias, attrition bias, and reporting bias, were assessed using the risk-of-bias graph and summary table. Studies that may have included some of the same patients in different publications (8, 15, 16, 17, 18) (similar authors, same institution, and overlapping recruiting periods) were only included once, using only the original published study.

### Statistical analysis

Data were processed using RevMan 5.3. Summary receiver operating characteristic (SROC) curves, sensitivity and specificity plots were applied to assess the performance of diagnostic tests. The weighted mean was estimated by using random-effects with

95% CI, and the Cochrane Q and  $I^2$  statistics were used to assess heterogeneity. A fixed-effect model was selected if there was no unexplained statistical heterogeneity, otherwise, a random-effect model was used in the meta-analysis. A  $P$  value  $<0.05$  was considered to be statistically significant.

## Results

### Study characteristic

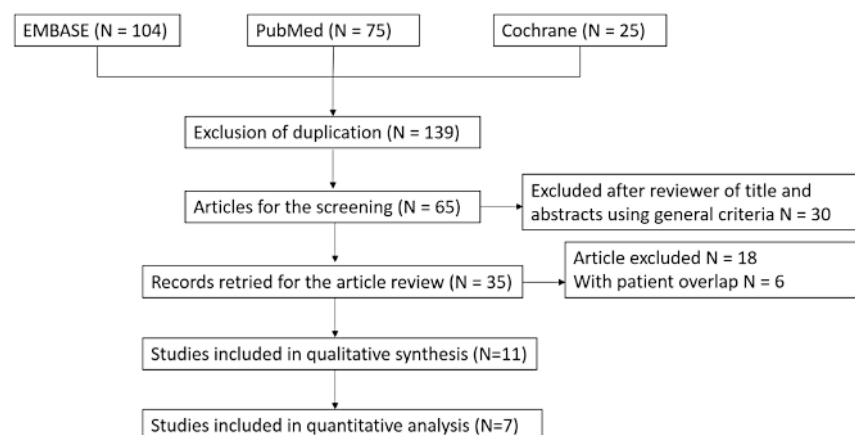
A total of 204 studies were searched in our systematic literature. One hundred forty-nine of these studies were duplicate publications, and 30 did not meet inclusion criteria. Twenty-eight studies were ruled out because (1) 18 were not scientific publications, (2) six had patient, institution and recruitment period overlap, and (3) four did not include qualitative or quantitative analysis (Fig. 1). As a result, seven studies encompassing 3668 patients were selected (7, 9, 10, 11, 12, 13, 14) with baseline demographics and characters summarized in Table 1. Three of these studies examined the sensitivity and specificity of MP and WM to detect angiographic evidence of in hospital-ACS, while six also looked at the predictive value of a WM abnormality (WMA) with or without a MP abnormality (MPA) to detect longer term MACE, including death/nonfatal myocardial infarction (death/NFMI). The characteristics of MCE, type of contrast agents used, resting MCE analysis procedure, criteria for determining MPA or WMA, reference standard, and clinical end-point for each individual study were summarized in Table 2. An example of a resting WMA with and without accompanying MPA are displayed in Fig. 2 and Video 1, and Fig. 3 and Video 2. Risk-of-bias graph and summary table showed a low risk of bias across all included studies (Fig. 4).

### Diagnostic accuracy of resting WM and MP to detect ACS

The meta-analysis of MP, WM, ECG, and initial troponin to detect in hospital ACS is shown in Fig. 5. SROC plot was based on the five different methods. Figure 5A demonstrates that a resting MPA with WMA had the highest area (0.80–0.90), while analyzing MP alone, WM alone, and initial troponin alone had fair AUC values (0.70–0.80). The initial ECG had low sensitivity and specificity (0.50–0.60). Of the three studies which performed ACS risk calculation using the MP+WM, MP, WM and ECG models in Fig. 5B, the sensitivity values were 0.79–0.92, 0.76–0.93, 0.51–0.79 and 0.33–0.86, respectively, while the specificity values were 0.56–0.93, 0.60–0.93, 0.57–0.97 and 0.34–0.82, respectively. For the older less sensitive troponin assays, the sensitivity values were 0.51–0.54, while the specificity values were 0.91–0.97. For detecting an in hospital ACS, a combined WMA/MPA provided incremental value over abnormal WM alone, MP alone, ECG and troponin tests.

### Predicting MACE with resting MCE

To investigate the risk of subsequent MACE at longer term follow up, the predictive value of abnormal resting WM was examined in the context of whether there was an associated MPA. Figure 6 revealed a significantly elevated risk of MACE in patients with (1) MPA + WMA (RR, 6.06; 95% CI, 5.11–7.18,  $P < 0.001$ ) when compared with normal MP/normal WM (MPN+WMN), (2) abnormal WM/normal MP (WMA+MPN, RR, 3.37; 95% CI, 2.74–4.14;  $P < 0.001$  vs MPN+WMN), and (3) MPA + WMA vs resting WMA with normal MP (RR, 1.66; 95% CI, 1.45–1.90;  $P < 0.001$ ) with high heterogeneity in each comparison ( $I^2 = 94\%$ , 75% and 95%, respectively). Note this predictive value of resting WM and MP



**Figure 1**  
Preferred reporting items for systematic review and meta-analysis (PRISMA) flowchart of the process of study selection.

**Table 1** Baseline characteristics of selected studies that met inclusion criteria for the meta-analysis.

Study	Patients (n)	Study design	Recruitment period	Length of follow-up	Age (y)	Men (%)	Diagnosis of patients	Smokers (%)	DM (%)	HT (%)	Hyperlipidemia (%)	Family history of CAD (%)
Porter <i>et al.</i> (2013) (7)	1028	S, P	2007.10–2011.12	2.6 y	60 ± 13	48	Suspected cardiac CP or shortness of breath	35	26	61	54	33
Wei <i>et al.</i> (2010) (9)	1166	S, P	NA	NA	60 ± 14	54	Suspected cardiac CP and no ST-segment elevation	66	28	65	52	28
Tong <i>et al.</i> (2005) (8)	957	S, P	2000.10–2003.1	NA	60 (32–92)	52	CP and a nondiagnostic electrocardiogram	27	28	66	53	47
Rinkevich <i>et al.</i> (2005) (10)	1017	S, P	NA	8 m	60 ± 11	53	Suspected cardiac CP and no ST-segment elevation	28	29	65	53	NA
Kaul <i>et al.</i> (2004) (13)	203	M, P	2001.10–2002.12	9 m	62 ± 8	68	Suspected cardiac CP and no ST-segment elevation	63	21	50	NA	54
Kang <i>et al.</i> (2005) (11)	114	S, P	1998.1–1998.9	NA	60 ± 10	64	Suspected cardiac CP and no ST-segment elevation	NA	27	NA	NA	NA
Korosoglou <i>et al.</i> (2004) (14)	98	S, P	NA	NA	59 ± 15	60	Suspected cardiac CP and no ST-segment elevation	NA	22	47	45	NA
Hagendorff <i>et al.</i> (2004) (12)	42	S, P	NA	NA	NA	NA	Suspected cardiac CP	NA	NA	NA	NA	NA

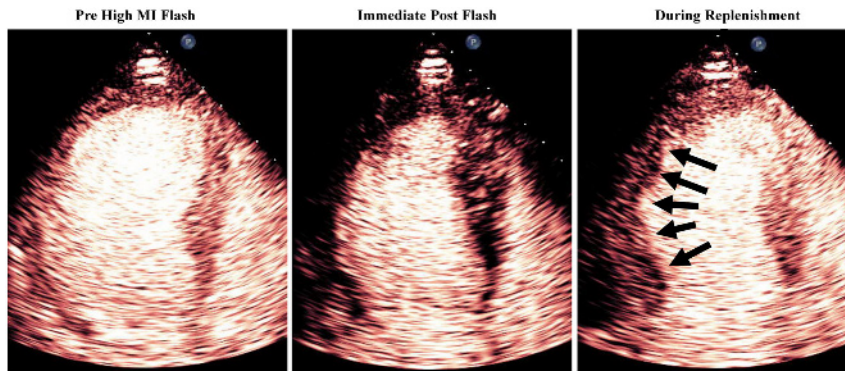
ACS, acute coronary syndrome; CAD, coronary artery disease; CP, chest pain; DM, diabetes mellitus; HT, hypertension; M, multicenter; NA, not available; P, prospective; S, single center.

**Table 2** Summary of the characteristics of resting MCE, golden standard and end-point definition for each individual study.

Study	Contrast agents	Procedure	No. of segments	Criterion for abnormal MP	Criterion for abnormal WM	Reference standard	End-point definition
Porter <i>et al.</i> (2013) (7)	Definity: CI 3% with 4–6 ml/min	RTMCE; Low-mechanical index (<0.2), brief high mechanical index impulses	17	Fixed or inducible abnormalities	1-normal; 2-hypokinetic; 3-akinetic; 4-dyskinetic	CA	Death, NFMI, revascularization
Wei <i>et al.</i> (2010) (9)	Optison: CI 5% with 3 ml/min	RTMCE; Low-mechanical index (<0.3), brief high mechanical index impulses (1.0)	14	Maximal myocardial opacification was not seen within a segment by 5 cardiac cycles.	0-normal; 1-hypokinetic; 2-akinetic; 3-dyskinetic	NA	Cardiac death, NFMI, LVEF
Tong <i>et al.</i> (2005) (8)	Optison: CI 5% with 3 ml/min	RTMCE; Low-mechanical index (<0.3), brief high mechanical index impulses (1.0)	14	Maximal myocardial opacification was not seen within a segment by 5 cardiac cycles.	1-normal; 2-hypokinetic; 3-akinetic; 4-dyskinetic	CA	Death, NFMI, USAP, revascularization,
Rinkevich <i>et al.</i> (2005) (10)	Optison: CI 5% with 3 ml/min	RTMCE; Low-mechanical index (<0.3), brief high mechanical index impulses (1.0)	14	Maximal myocardial opacification was not seen within a segment by 5 cardiac cycles.	1-normal; 2-hypokinetic; 3-akinetic; 4-dyskinetic	NA	Cardiac death, NFMI, USAP, revascularization, CHF hospitalization
Kang <i>et al.</i> (2005) (11)	Sonazoid: BI 0.5 mL	RTMCE; Low-mechanical index, brief high mechanical index impulses (1.3–1.6), end-systole triggered	NA	Maximal myocardial opacification was not seen within a segment by 4–6 cardiac cycles.	1-normal; 2-hypokinetic; 3-akinetic; 4-dyskinetic	CA	Death, NFMI, ACS, revascularization
Kaul <i>et al.</i> (2004) (13)	PESDA: CI 10% with 0.8–3 mL/min	RTMCE; Low-mechanical index, brief high mechanical index impulses (1.0)	14	Maximal myocardial opacification was not seen within a segment by 5 cardiac cycles.	1-normal; 2-hypokinetic; 3-akinetic; 4-dyskinetic	SPECT	Cardiac death, NFMI, revascularization
Korosoglou <i>et al.</i> (2004) (14)	SonoVue: BI 1.0–1.5 mL	RTMCE; Low-mechanical index (0.14–0.18), brief high mechanical index impulses	NA	0-no opacification; 1-severely decreased; 2-mildly decreased; 3-homogeneous	1-normal; 2-hypokinetic; 3-akinetic; 4-dyskinetic	CA	NFMI, ACS, USAP, Perimyocarditis
Hagendorff <i>et al.</i> (2004) (12)	Optison: BI 0.4 mL	RTMCE; Low-mechanical index, end-systole triggered	NA	1-homogeneous enhancement; 2-patchy enhancement; 3-no enhancement	NA	CA	NA

ACS, acute coronary syndrome; BI, bolus injection; CA, coronary angiography; CI, continuous infusion; MP, myocardial perfusion; NA, not available; NFMI, nonfatal myocardial infarction; RTMCE, real-time myocardial contrast echocardiography; SPECT, single-photon emission computed tomography; USAP, unstable angina pectoris; WM, wall motion.





**Figure 2**

An example of end systolic A3C chamber perfusion images with arrows delineating the perfusion defect in the mid inferolateral and distal lateral segments.

was seen in both the ED studies as well as in a less acute setting of outpatient evaluations for suspected symptomatic CAD.

### Video 1

Resting WMA with accompanying MPA. View Video 1 at <http://movie-usa.glencoesoftware.com/video/10.1530/ERP-20-0023/video-1>.

### Video 2

Resting WMA without accompanying MPA. View Video 2 at <http://movie-usa.glencoesoftware.com/video/10.1530/ERP-20-0023/video-2>.

### Death/NFMI events elevated in abnormal resting MCE patients

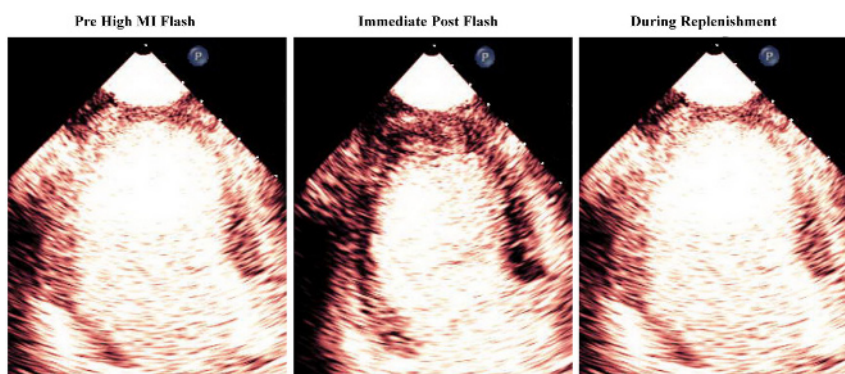
The outcome of all-cause death/NFMI was increased in patients with resting MPA/WMA (RR, 14.26; 95% CI, 10.26–19.81;  $P < 0.001$  compared to MPN+WMN, Fig. 7A) and WMA with normal resting MP (RR, 6.38; 95% CI, 4.29–9.63;  $P < 0.001$  compared to MPN/WMN, Fig. 7B), with  $I^2$  values of 84 and 7%, respectively. In addition, there was a significant higher risk of death/nonfatal MI in the resting MPA/WMA patients (RR, 2.20; 95% CI, 1.78–2.72;

$P < 0.001$ , Fig. 7C) when compared to patients with resting WMA but normal MP with high heterogeneity ( $I^2 = 88\%$ ).

### Discussion

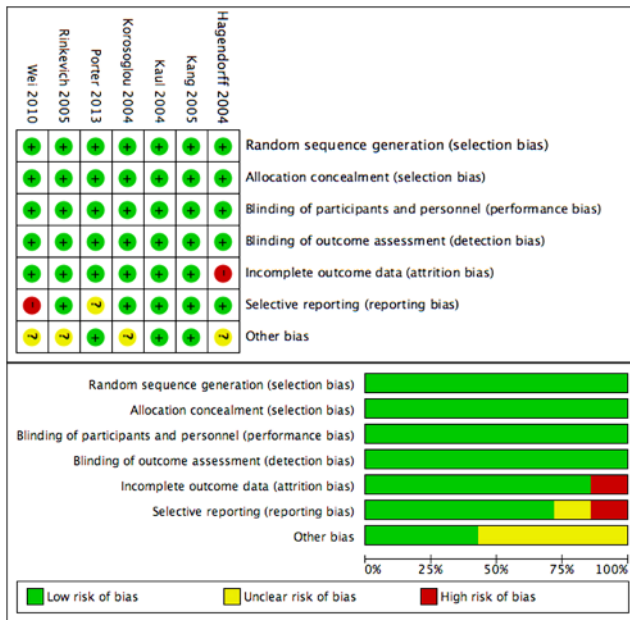
This meta-analysis is the first to evaluate the incremental diagnostic and prognostic value of combining WM and MP during resting MCE in patients with suspected symptomatic CAD and nondiagnostic ECG in both an urgent ED and semi-urgent echocardiography lab setting. In this combined setting, we demonstrated the critical role of assessing both MP and WM under resting conditions to evaluate risk. In the ED setting, we confirmed that the pooled sensitivity and specificity of a resting MP and WM abnormality added value to clinical and biochemical markers for the detection of ACS. In this setting, a combined WMA and MPA provided risk stratification for all adverse cardiac events, as well as harder end points, such as death/NFMI.

When compared to single-photon emission CT myocardial perfusion imaging (19), coronary CT angiography (20) and stress cardiovascular MRI (21) in the emergent setting, resting MCE has advantages in detecting suspected CAD in the ED, in that it is more practical, portable, and less costly than other procedures (18).



**Figure 3**

An example of resting end systolic images of a wall motion abnormality in the mid inferolateral and distal lateral segments without accompanying perfusion defects (arrows).



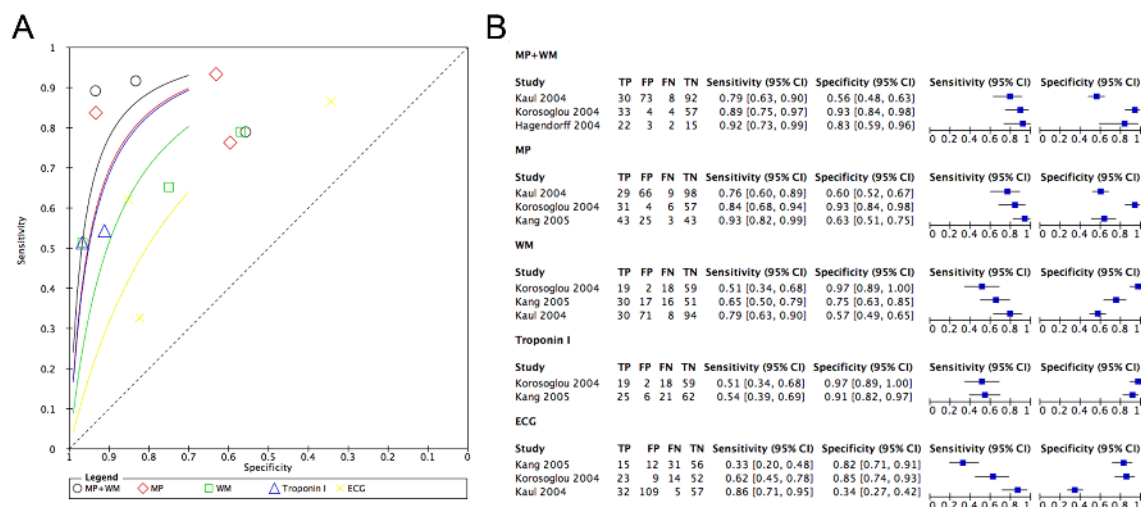
**Figure 4**  
Risk-of-bias graph and summary table of review authors' judgments about each risk-of-bias item presented as percentages across all included studies.

Although not all of the studies in this meta-analysis utilized ultrasound contrast to enhance regional WM, real-time very low mechanical index imaging techniques are now recommended to assess perfusion and regional function simultaneously (22, 23). This has permitted the detection of subendocardial wall thickening, and further improved the ability of echocardiography to detect resting regional WMA (6, 7). It is interesting that in the context

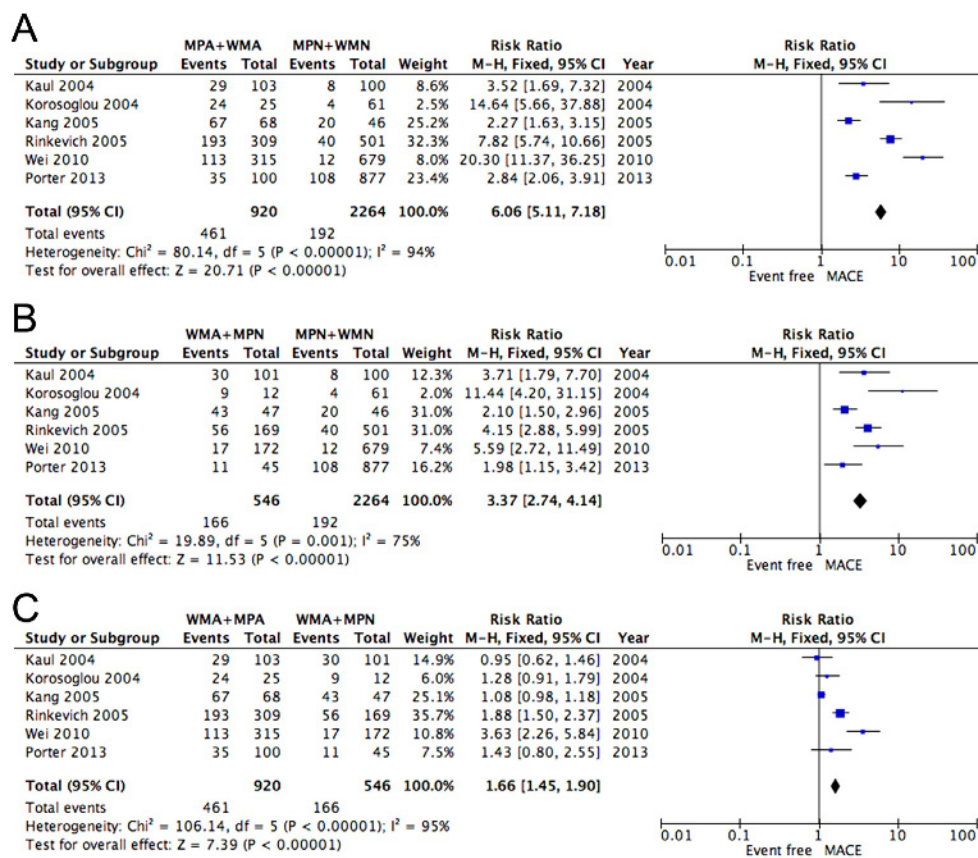
of resting studies, the prognostic ability of a resting WMA can be further stratified by assessing whether MP is abnormal or normal. In the acute setting, this may imply that if MP is restored in the presence of a resting WMA it may indicate reperfusion has occurred and the risk to the patient is less, while a combined MPA/WMA would indicate ongoing ischemia and thus higher risk of events (infarction, death). In the less acute setting of a patient being referred for stress echocardiography because of suspected symptomatic CAD, a resting WMA with MPA may imply a prior infarction or ongoing ischemia. Although this meta-analysis cannot identify which of these two situations was present, a resting WMA with or without MPA in this setting was still an independent predictor of outcome irrespective of subsequent stress echocardiogram findings (7).

### Meta-analysis limitations

The selection of three ED-based studies (Kang 2005 (11), Korosoglou 2004 (14), Kaul 2004 (13) and Hagendorff 2004 (12)) was conducted to obtain the diagnostic accuracy of resting MCE, WM, ECG and troponin I for the ACS risk calculation, respectively. In these studies, WM was not analyzed with contrast, and therefore the prevalence of resting WMA may have been underestimated. Similarly, with new high sensitivity troponin assays, the value of this biomarker in detecting an ACS may have improved, although at the cost of lower specificity (24). In the original ED studies, the resting WM and MP data was not used in



**Figure 5**  
SROC curves (A), sensitivity and specificity plots (B) comparing the diagnostic accuracy of MP + WM, MP, WM, ECG and troponin I for the detection of ACS, respectively.



**Figure 6**

Forest plot depicting the risk of major adverse cardiac events (MACE) between (A) abnormal MP and abnormal WM (MPA + WMA) and normal MP/normal WM (MPN + WMN), (B) abnormal WM/normal MP (WMA + MPN) vs MPN + WMN, and (C) MPA + WMA vs WMA + MPN patients.

clinical decision making (8, 10), but subsequent studies have prospectively validated the incremental value of both contrast-enhanced WM and MP in predicting outcome when used in clinical decision making and when added to clinical, EKG, and biomarker data (9). In the stress echocardiography setting, the resting data is often accompanied by re-analysis of WM and MP during stress conditions. However, in the prospective real-time myocardial contrast stress echocardiographic study that met criteria for this meta-analysis, a *resting* contrast-enhanced WMA was the only multivariate predictor of outcome (7). Nonetheless, our studies were mostly based on studies performed at single centers, and larger multi-center studies are necessary to confirm the feasibility and reproducibility of resting real-time MCE in detecting ACS and predicting clinical cardiac outcomes in the patient with suspected symptomatic CAD.

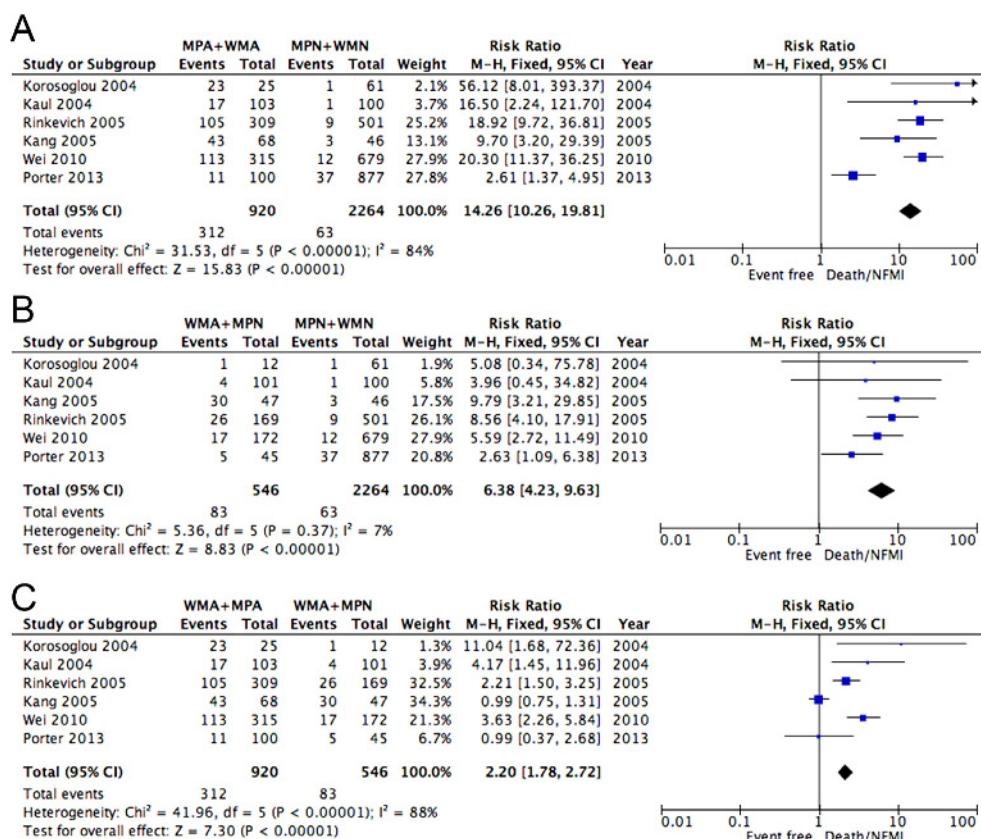
Another limitation is that all studies in the meta-analysis were performed prior to 2013, in single centers

that have recognized expertise with the MCE technique. Furthermore, the majority of the data originates from only two centers. Although this may limit the generalizability of the data, it should be noted that both the 2017 European and 2018 American guidelines for utilization of ultrasound enhancing agents have emphasized resting real-time MCE to detect suspected ACS, with the American guidelines giving contrast enhanced WMA a Class I level of recommendation and MP a Class IIa indication (23, 25).

## Conclusion

Resting MP and WM assessment utilizing real-time MCE is an effective diagnostic and prognostic tool in patients with suspected symptomatic CAD and a nondiagnostic ECG in a wide variety of clinical settings.





**Figure 7**

Forest plot depicting the risk of death/NFMI between (A) MPA + WMA and MPN + WMN, (B) WMA + MPN vs MPN + WMN as well as (C) MPA + WMA vs WMA + MPN patients.

## Declaration of interest

Doctor Porter has served as a consultant for Lantheus Medical and received equipment support from Philips Healthcare. He has served as a speaker for Northwest Imaging. The other authors have nothing to disclose.

## Funding

This study was partially supported by the National Natural Science Foundation of China (Grant No. 81871359), by Jiangsu Provincial Key Discipline of Medicine (ZDXKA2016003), by the Natural Science Foundation of Jiangsu Province (BK20161057), by the Postgraduate Research & Practice Innovation Program of Jiangsu Province (KYCX18\_1478) and the China Scholarship Council (201808320318). This was also supported by the Theodore F Hubbard Foundation at the University of Nebraska Medical Center.

## Acknowledgement

The authors thank Alyssa Elwood for her administrative assistance with this manuscript.

## References

- McMahon GC, Yates DW & Hollis S. Unexpected mortality in patients discharged from the emergency department following an episode of nontraumatic chest pain. *European Journal of*

*Emergency Medicine* 2008 **15** 3–8. (<https://doi.org/10.1097/MEJ.0b013e32827b14cd>)

- Sun BC, Laurie A, Fu R, Ferencik M, Shapiro M, Lindsell CJ, Diercks D, Hoekstra JW, Hollander JE, Kirk JD, *et al.* Association of early stress testing with outcomes for emergency department evaluation of suspected acute coronary syndrome. *Critical Pathways in Cardiology* 2016 **15** 60–68. (<https://doi.org/10.1097/HPC.000000000000068>)
- Chase M, Robey JL, Zogby KE, Sease KL, Shofer FS & Hollander JE. Prospective validation of the thrombolysis in myocardial infarction risk score in the emergency department chest pain population. *Annals of Emergency Medicine* 2006 **48** 252–259. (<https://doi.org/10.1016/j.annemergmed.2006.01.032>)
- Lee TH, Cook EF, Weisberg M, Sargent RK, Wilson C & Goldman L. Acute chest pain in the emergency room: identification and examination of low-risk patients. *Archives of Internal Medicine* 1985 **145** 65–69. (<https://doi.org/10.1001/archinte.1985.00360010085013>)
- Selker HP, Griffith JL & D'agostino RB. A tool for judging coronary care unit admission appropriateness, valid for both real-time and retrospective use: a time-insensitive predictive instrument (TIPI) for acute cardiac ischemia: a multicenter study. *Medical Care* 1991 **29** 610–627. (<https://doi.org/10.1097/00005650-199107000-00002>)
- Thomas D, Xie F, Smith LM, O'Leary E, Smith K, Olson J, Nalty K, Hess R, Graham M, Therrien S, *et al.* Prospective randomized comparison of conventional stress echocardiography and real-time perfusion stress echocardiography in detecting significant coronary artery disease. *Journal of the American Society of Echocardiography* 2012 **25** 1207–1214. (<https://doi.org/10.1016/j.echo.2012.08.016>)

- 7 Porter TR, Smith LM, Wu J, Thomas D, Haas JT, Mathers DH, Williams E, Olson J, Nalty K, Hess R, *et al.* Patient outcome following 2 different stress imaging approaches: a prospective randomized comparison. *Journal of the American College of Cardiology* 2013 **61** 2446–2455. (<https://doi.org/10.1016/j.jacc.2013.04.019>)
- 8 Tong KL, Kaul S, Wang XQ, Rinkevich D, Kalvaitis S, Belcik T, Lepper W, Foster WA & Wei K. Myocardial contrast echocardiography versus thrombolysis in myocardial infarction score in patients presenting to the emergency department with chest pain and a nondiagnostic electrocardiogram. *Journal of the American College of Cardiology* 2005 **46** 920–927. (<https://doi.org/10.1016/j.jacc.2005.03.076>)
- 9 Wei K, Peters D, Belcik T, Kalvaitis S, Womak L, Rinkevich D, Tong KL, Horton K & Kaul S. A predictive instrument using contrast echocardiography in patients presenting to the emergency department with chest pain and without ST-segment elevation. *Journal of the American Society of Echocardiography* 2010 **23** 636–642. (<https://doi.org/10.1016/j.echo.2010.03.013>)
- 10 Rinkevich D, Kaul S, Wang XQ, Tong KL, Belcik T, Kalvaitis S, Lepper W, Dent JM & Wei K. Regional left ventricular perfusion and function in patients presenting to the emergency department with chest pain and no ST-segment elevation. *European Heart Journal* 2005 **26** 1606–1611. (<https://doi.org/10.1093/eurheartj/ehi335>)
- 11 Kang DH, Kang SJ, Song JM, Choi KJ, Hong MK, Song JK, Park SW & Park SJ. Efficacy of myocardial contrast echocardiography in the diagnosis and risk stratification of acute coronary syndrome. *American Journal of Cardiology* 2005 **96** 1498–1502. (<https://doi.org/10.1016/j.amjcard.2005.07.057>)
- 12 Hagendorff A, Goeckritz A, Pfeiffer D & Becher H. Myocardial t echocardiography demonstrates myocardial hypoperfusion in the LAD territory in patients with acute chest pain at rest – a prospective study using power Doppler harmonic imaging with intravenous bolus application. *European Journal of Echocardiography* 2004 **5** 132–141. ([https://doi.org/10.1016/S1525-2167\(03\)00055-6](https://doi.org/10.1016/S1525-2167(03)00055-6))
- 13 Kaul S, Senior R, Firschke C, Wang XQ, Lindner J, Villanueva FS, Firozan S, Kontos MC, Taylor A, Nixon IJ, *et al.* Incremental value of cardiac imaging in patients presenting to the emergency department with chest pain and without ST-segment elevation: a multicenter study. *American Heart Journal* 2004 **148** 129–136. (<https://doi.org/10.1016/j.ahj.2003.12.041>)
- 14 Korosoglou G, Labadze N, Hansen A, Selter C, Giannitsis E, Katus H & Kuecherer H. Usefulness of real-time myocardial perfusion imaging in the evaluation of patients with first time chest pain. *American Journal of Cardiology* 2004 **94** 1225–1231. (<https://doi.org/10.1016/j.amjcard.2004.07.104>)
- 15 Li X, He S, Zhang YS, Chen Y & He JC. Resting myocardial contrast echocardiography for the evaluation of coronary microcirculation dysfunction in patients with early coronary artery disease. *Clinical Cardiology* 2016 **39** 453–458. (<https://doi.org/10.1002/clc.22548>)
- 16 Laiq Z, Smith LM, Xie F, Chamsi-Pasha M & Porter TR. Differences in patient outcomes after conventional versus real time perfusion stress echocardiography in men versus women: a prospective randomized trial. *Heart* 2015 **101** 559–564. (<https://doi.org/10.1136/heartjnl-2014-306869>)
- 17 Kalvaitis S, Kaul S, Tong KL, Rinkevich D, Belcik T & Wei K. Effect of time delay on the diagnostic use of contrast echocardiography in patients presenting to the emergency department with chest pain and no S-T segment elevation. *Journal of the American Society of Echocardiography* 2006 **19** 1488–1493. (<https://doi.org/10.1016/j.echo.2006.06.010>)
- 18 Wyrick JJ, Kalvaitis S, McConnell KJ, Rinkevich D, Kaul S & Wei K. Cost-efficiency of myocardial contrast echocardiography in patients presenting to the emergency department with chest pain of suspected cardiac origin and a nondiagnostic electrocardiogram. *American Journal of Cardiology* 2008 **102** 649–652. (<https://doi.org/10.1016/j.amjcard.2008.05.008>)
- 19 Bailliez A, Lairez O, Merlin C, Piriou N, Legallois D, Blaire T, Agostini D, Valette F & Manrique A. Left ventricular function assessment using 2 different cadmium-zinc-telluride cameras compared with a  $\gamma$ -camera with cardiofocal collimators: dynamic cardiac phantom study and clinical validation. *Journal of Nuclear Medicine* 2016 **57** 1370–1375. (<https://doi.org/10.2967/jnumed.115.168575>)
- 20 Korosoglou G, Giusca S, Gitsioudis G, Erbel C & Katus HA. Cardiac magnetic resonance and computed tomography angiography for clinical imaging of stable coronary artery disease. Diagnostic classification and risk stratification. *Frontiers in Physiology* 2014 **5** 291. (<https://doi.org/10.3389/fphys.2014.00291>)
- 21 Rudolph A, Abdel-Aty H, Bohl S, Boyé P, Zagrosek A, Dietz R & Schulz-Menger J. Noninvasive detection of fibrosis applying contrast-enhanced cardiac magnetic resonance in different forms of left ventricular hypertrophy relation to remodeling. *Journal of the American College of Cardiology* 2009 **53** 284–291. (<https://doi.org/10.1016/j.jacc.2008.08.064>)
- 22 Mulvagh SL, Rakowski H, Vannan MA, Abdelmoneim SS, Becher H, Bierig SM, Burns PN, Castello R, Coon PD, Hagen ME, *et al.* American Society of Echocardiography consensus statement on the clinical applications of ultrasonic contrast agents in echocardiography. *Journal of the American Society of Echocardiography* 2008 **21** 1179–1201; quiz 1281. (<https://doi.org/10.1016/j.echo.2008.09.009>)
- 23 Porter TR, Mulvagh SL, Abdelmoneim SS, Becher H, Belcik JT, Bierig M, Choy J, Gaibazzi N, Gillam LD, Janardhanan R, *et al.* Clinical applications of ultrasonic enhancing agents in echocardiography: 2018 American Society of Echocardiography guidelines update. *Journal of the American Society of Echocardiography* 2018 **31** 241–274. (<https://doi.org/10.1016/j.echo.2017.11.013>)
- 24 Melki D, Lugnegard J, Alfredsson J, Lind S, Eggers KM, Lindahl B & Jernberg T. Implications of introducing high-sensitivity cardiac troponin T into clinical practice. *Journal of the American College of Cardiology* 2015 **65** 1655–1664. (<https://doi.org/10.1016/j.jacc.2015.02.044>)
- 25 Senior R, Becher H, Monaghan M, Agati L, Zamorano J, Vanoverschelde JL, Nihoyannopoulos P, Edvardsen T, Lancellotti P, EACVI Scientific Documents Committee for 2014–16 and 2016–18, *et al.* Clinical practice of contrast echocardiography: recommendation by the European Association of Cardiovascular Imaging (EACVI) 2017. *European Heart Journal Cardiovascular Imaging* 2017 **18** 1205–1205af. (<https://doi.org/10.1093/ehjci/jex182>)

Received in final form 2 July 2020

Accepted 20 July 2020

Accepted Manuscript published online 21 July 2020